



ISSN (P): 2617-7226  
ISSN (E): 2617-7234  
www.patholjournal.com  
2019; 2(1): 14-17  
Received: 09-11-2018  
Accepted: 13-12-2018

**Dr. Atul Shrivastava**  
Associate professor, Dept of  
Pathology, GMERS Medical  
College, Himmatnagar,  
Gujarat, India

**Dr. Nilay Shah**  
Assistant Professor, Dept of  
Pathology, GMERS Medical  
College, Himmatnagar,  
Gujarat, India

**Dr. Sunita Goyal**  
Assistant Professor, Dept of  
Pathology, GMERS Medical  
College, Himmatnagar,  
Gujarat, India

**Dr. Cherry K Shah**  
Professor & Head, Dept. of  
Pathology, Smt NHL Medical  
College, Ahmedabad, Gujarat,  
India

**Correspondence**  
**Nilay Shah**  
Assistant Professor, Dept of  
Pathology, GMERS Medical  
College, Himmatnagar,  
Gujarat, India

## RBC histogram: Utility in diagnosis of various anemia

**Atul Shrivastava, Nilay Shah, Sunita Goyal and Cherry K Shah**

**DOI:** <https://doi.org/10.33545/pathol.2019.v2.i1a.04>

### Abstract

**Introduction:** Anemia is a common health problem in overall world especially in developing countries. Early and accurate diagnosis is needed to decide correct line of treatment.

**Material & Methods:** The study was conducted in Hematology laboratory of medical college hospital for a period of 12 month during January 2018 to December 2018. Total 1500 anemic patients of 10-70 year of age were included in the study. Interpretation of RBC Histogram and peripheral smear examination was done in each case.

**Results:** Out of total 1500 anemic cases, microcytic anemia is most common cause followed by normocytic, Dimorphic and macrocytic anemia. Female patients are more than male patients and most common involved age group is 31-40 years followed by 21-30 years.

**Discussion:** Interpretation of RBC histograms is useful method for initial diagnosis of anemia and can be used for screening purpose to screen large population.

**Keywords:** Anemia, histogram, peripheral blood smear examination, microcytic anemia

### Introduction

Peripheral blood smear (PBS) examination under microscope is a routine work of every hematology laboratory. The manual examination of cellular details is cumbersome, time consuming and suffers from inter-observer variation. With the advent of automated hematology analyzers microscopic examination of blood smear has taken a backseat in diagnosis of anemia [1].

The automated hematology analyzers based on impedance principle and relies on the change in conductance as each cell passes through an aperture. This change in conductance results in development of an electrical pulse which's amplitude is proportional to the cell volume. The results are displayed as histogram and as figures. RBC histogram is a graphic representation of particle size distribution (cell frequencies verses size). Shift in one direction or another can be of diagnostic importance and in association with other CBC parameters such as RBC distribution width (RDW) and RBC indices (MCV, MCH, MCHC) it has been found abnormal in various hematological conditions [2-4]. A lot of studies [5-9] have been done to assess the efficacy and significance of red blood cell parameters in different hematological conditions. We undertake this study to study RBC's histograms in various anemias and to compare our findings with available literature.

### Aims and Objective

1. To study RBC Histogram obtained from automated hematology analyzer along with peripheral smear examination.
2. To observe utility of RBC histogram as diagnostic tool for various RBC disorders.

### Materials and Methods

The data obtained from Hematology laboratory, GMERS Medical College, Himmatnagar for a period of 12 month during January 2018 to December 2018. It is an Observational study done having sample size of 1500 anemic patients. Sample is considered anemic Anemia as per WHO reference range. Blood sample collected in EDTA vacuette and in all cases RBC histogram and other findings were obtained from automated hematology analyzer and Peripheral smear examination was also done on each slide. In the present study, we include age range 10-70 years. Permission was taken from Institutional Ethics Committee to conduct the study. Statistical analysis was done on Microsoft excel.

Inclusion criteria: 1) all anemic samples as per WHO reference range.

Exclusion Criteria: 1) Children below 10 years were excluded.

2) Patient having leukocytosis, leukemaioid reaction, leukaemia, and platelet Disorders were excluded from study.

Males and 814 samples were from females and 0.84:1 is the male female ratio of the study.

Results are given in tabulated form started from Table no. 1 to Table no. 5

**Results and Analysis**

Out of total 1500 anemic samples 686 samples were from

**Table 1:** Age and gender distribution in study

Age range	10-20	21-30	31-40	41-50	51-60	61-70	Overall
Number of cases(Percentage)	56 (3.73)	352 (23.46)	614 (40.93)	260 (17.33)	130 (8.66)	88 (5.87)	1500 (100)
Number of Male	22	110	196	107	55	38	528
Number of Female	34	242	418	153	75	50	972
M:F	1.4:2	1:2	1:2	1.4:2	1.4:2	1.6:2	1:2

**Table 2:** Case Distribution as per types of anemia

S. no.	Type of anemia	Number of cases (Percentage)
1	Microcytic	1050 (70%)
2	Macrocytic	60 (4%)
3	Normocytic	270 (18%)
4	Dimorphic	120 (8%)

**Table 3:** Distribution of RBC histogram in present study

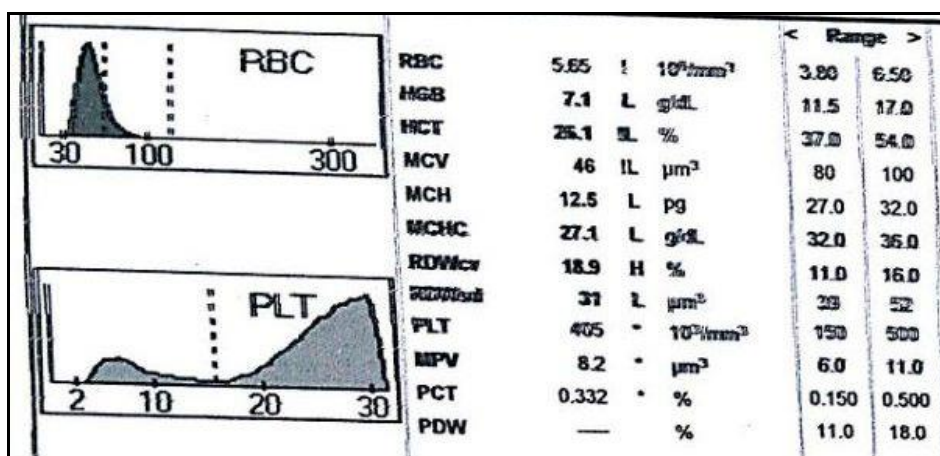
S. no.	Type of histogram	Percentage
1	Normal curve	18%
2	Left shift	29%
3	Right shift	06%
4	Broad base	40%
5	Short peak	02%
6	Bimodal peak	05%

**Table 4:** Presentation of RBC histograms in different types of anemia.

Type of anemia	Normal curve	Left shift	Right shift	Broad base	Short peak	Bimodal
Normocytic	13	-	-	05	-	-
Microcytic	03	28	-	34	01	04
Macrocytic	-	-	03	-	01	-
Dimorphic	02	01	03	01	-	01

**Findings of RBC Histograms:** In present study we found that, maximum number of cases (70%) were of Microcytic hypochromic anemia and showed various types of histograms. Among all 03% histograms were normal,28% were having left shifted curve,34% showed broad based curve,01% showed short peak and Bimodal peaked histogram was shown by 04% of total cases. Normocytic normochromic anemia having total 18% cases and among them 13% showed normal curve and 05% of cases showed broad based curve. 04% cases of macrocytic anemia were found on microscopy which showed right shift curve in 03% of cases and showed short peak curve histogram in rest 01% of cases. In cases of Dimorphic anemia we observed total 08% cases of dimorphic anemia, and they showed normal curve in 02%, left shift curve in 01%,right shift curve in 03%, broad based curve in 01% and bimodal curve in 01%.

**Correlation with Peripheral smear findings:** In our study we observe that cases of Microcytic hypochromic anemia were showing less than normal range of MCV & MCH with normal MCHC and increased Red cell Distribution Width (RDW) and this finding is correlated with anisopoikilocytosis which was seen on the microscopic examination of peripheral blood smear (PBS). Cases of Macrocytic anemia show increase in MCV, MCH and RDW with normal MCHC. The cases of Normocytic Normochromic anemia showed normal limit of MCV, MCH and MCHC and occasional cases having mildly increased RDW. In present study cases of Dimorphic anemia showed normal range of MCV, MCH and MCHC while RDW is increased due to high degree of anisocytosis and poikilocytosis which was observed in the PBS.



**Fig 1:** Microcytic RBCs showing left shift.

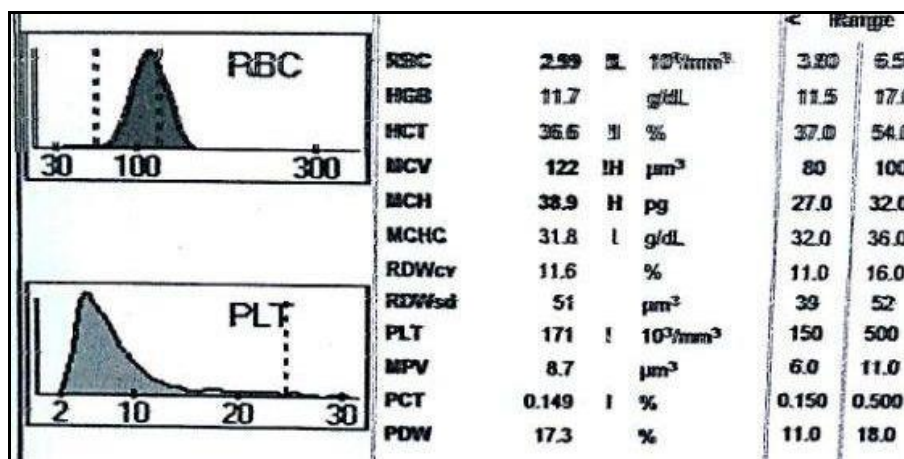


Fig 2: Macrocytic RBCs showing right shift.

**Discussion**

It is already stated in various literatures that RBC Histogram is a graphical representation obtained from automated hematology analyzer. RBC histogram is standard part of complete blood picture which provides clues in diagnosis of various RBC disorders and give valuable information regarding to RBC parameters like RDW, MCH and MCV [1, 2]. Normally curve is symmetrical bell shaped or Gaussian distribution. Normal curve falls within normal range of MCV which is 80-100 fl. The RBC histogram in the hematology analyzer displays the ranges for RBC are between 24fl and 360fl. The analyzer counts only those RBC's with volume sizes between 36fl to 360fl as red cells and cells which are counted in the range 24fl to 36 fl are not included in the RBC count and rejected by counter. Normally below 36fl size space is clear and histogram is begin from base line but if histogram begin above the base line indicates the presence of small particles like platelet clumps, malaria parasite, microspherocytes, normoblast, elliptocytes, bacteria, etc [10, 11]. WBC's does not affect the RBC count until their number is increased by more than 50000.

In present study of 1500 cases, maximum numbers of cases are having Microcytic anemia (70%) followed by normocytic (18%), Dimorphic (8%) and Macrocytic (4%). Other studies like sandhya *et al.* [5] Chavda J *et al.* [6] & Byna Syam Sundara Rao *et al.* [8] were also found similar findings regarding distribution of anemia cases. Our study of RBC histogram showed normal curve (18%), left shift (29%), right shift (6%) Broad base (40%), short peak (2%) and bimodal (5%) and these findings regarding to RBC histogram were also correlated with other studies like sandhya *et al.* [5] Chavda J *et al.* [6] & Rao BSS *et al.* [8] (Table no. 5).

When RBC population is Homogenous it gives narrow distribution curve and a broad base curve usually denotes presence of more anisocytosis, which could be confirmed by PBS examination. Shift of histogram depends on the size of RBC, If cell size is more than normal (macrocytic RBC) shift is toward right and when size of cell is less than normal (microcytic RBC) shift is toward left. In present study, microcytic RBC show left sided shifted curve because of small size along with cases showing broad base curve that is because of high RDW which suggest presence of anisocytosis. Most of the cases of microcytic RBC are iron deficiency anemia and they predominantly belongs to

reproductive age group female, Iron deficiency during pregnancy is a common problem in our country [6, 12]. In cases of macrocytic anemia right shift with broad based curve means low Hb and macrocytic blood picture. Causes of macrocytosis may vary from benign to malignant and a complete approach is essential to determine the etiology [13]. although Macrocytosis may occur at any age, but it is more prevalent in old age [14-16]. In our study majority of cases of macrocytic anemia showed right shift curve. Right shift curve correlated well with increased MCV and MCH. The dimorphic blood picture is showing bimodal curve along with some case showing left and right shifting of curve. There is wide reasons for dimorphic blood picture which includes nutritional anemia, recent blood transfusion or therapy response to nutritional anemia and sideroblastic anemia, to know exact cause thorough evaluation is necessary [17, 18].

Table 5: Histogram curves in various studies.

Histogram	Sandhya <i>et al.</i> [5]	Chavda J <i>et al.</i> [6]	Rao BSS <i>et al.</i> [8]	Present study
Normal curve	15%	19%	17.7%	18%
Left shift	30%	27%	29.0%	29%
Right shift	6%	07%	5.45%	06%
Broad base	40%	38%	37.72%	40%
Bimodal	4%	3%	7.27%	05%
Short peak	5%	6%	2.7%	02%

**Conclusion**

RBC Histogram is an important tool of diagnosis when correct interpretation of curve is combined with findings of blood count parameters like red cell distribution width and red cell indices. By observing these curves we could give presumptive diagnosis of presence of fragments in blood, microcytic, macrocytic or dimorphic red cells. Histograms along with Blood indices and Hb value will guide us about RBC morphology. Histograms are useful tool for technologists it could guide them that which cases need actual detailed peripheral smear examination by experts. In our study findings of automated analyzer was very well correlated with the microscopic examination. Histogram alone could be used as screening method and when combined with PBS findings, they act as useful supplement and by correlating findings of both methods we could diagnose majority of anemia.

## References

1. Kumar A, Kushwaha R, Gupta C, Singh US. An analytical study on peripheral blood smears in anemia and correlation with cell counter generated red cell parameters. *J Appl Hemato.* 2013; 4:137-44.
2. Bessman JD, Gilmer PR Jr, Gardner FH. Improved classification of anemias by MCV and RDW. *Am J Clin Pathol.* 1983; 80:322-326.
3. Fossat C, David M, Harle JR *et al.* New parameters in erythrocyte counting. Value of histograms. *Arch Pathol Lab Med.* 1987; 111:1150-1154.
4. [http://www.medialabinc.net/spg579125/interpretation\\_of\\_red\\_blood\\_cell\\_RBC\\_histograms.aspx](http://www.medialabinc.net/spg579125/interpretation_of_red_blood_cell_RBC_histograms.aspx).
5. Sandhya I, Muhasin TP. Study of RBC Histogram in various anemias. *Journal of Evolution of Medical and Dental sciences.* 2014; 3(74):1521-34.
6. Chavda J, Goswami P, Goswami A. RBC histogram as diagnostic tool in anemias. *IOSR Journal of Dental and Medical Sciences.* 2015; 14(10):19-22.
7. Benie T, Constantino SH. The Red Cell Histogram and The Dimorphic Red Cell Population. *LAB Medicine.* 2011; 42(5):300-8.
8. Rao BSS, Vissa S, Rao NM, Grandhi B, Muramreddy V, Sirasala P. RBC Histogram as Supplementary Diagnostic Tool with Peripheral Smear Examination in Evaluating Anaemia. *Annals of Pathology and Laboratory Medicine.* 2017; 4(6):A668-672.
9. Dr. Poonam Radadiya *et al.* Automated red blood cell analysis compared with routine red blood cell morphology by smear review. *NHL Journal of medical sciences.* 2015; 4(1):53-57.
10. Gulati GL, Hyun BH. The Automated CBC. A current perspective. *Hematol Oncol Clin North Am.* 1994; 8(4):593-603.
11. Bessman JD. Red blood cell fragmentation: Improved detection and identification of causes. *Am j clin pathol.* 1988; 90(3):268-73.
12. Kakkar N, Makkar M. Red cell cytograms generated by an ADVIA 120 automated hematology analyzer: Characteristic patterns in common hematological conditions. *Lab Med.* 2009; 40:549-555.
13. Kaferle J, Strzoda CE. Evaluation of macrocytosis. *Am Fam Physician.* 2009; 79(3):203-8.
14. Argento V, Royslance J, Skudlarska B *et al.* Anemia prevalence in a home visit geriatric populations. *J Am Med Dir Assoc.* 2008; 9(6):422-6.
15. Younis M, Daugher GA, Dulanto JV, Njeim M, Kuriakose P. Unexplained macrocytosis. *South Med J.* 2013; 106(2):121-5.
16. McNamee T, Hyland T, Harrington J, Cadogan S, Honari B, Perera K *et al.* Haematinic deficiency and macrocytosis in middle-aged and older adults. *PLoS One.* 2013; 8(11):e77743.
17. Benie T constantino. CML health care INC, Mississauga, Ontario, Canada —The red cell histogram and the dimorphic red cell population doi:10.1309/LMF1UY85HEKBMIWO *Lab Medicine,* 2011; 42:300-308.
18. <http://statlab.tumblr.com/post/18770587328/lab-test-cbc-histograms>.