



ISSN (P): 2617-7226
ISSN (E): 2617-7234
www.patholjournal.com
2019; 2(1): 299-302
Received: 06-11-2018
Accepted: 10-12-2018

Bimalka Seneviratne
Associate Professor,
Consultant Pathologist,
Department of Pathology,
Cancer Research Centre,
Faculty of Medical Sciences,
University of Sri
Jayawardenepura, Sri Lanka

Review of the histological variants of papillary thyroid carcinoma and assessment of the prognostic factors

Bimalka Seneviratne

DOI: <https://doi.org/10.33545/pathol.2019.v2.i1.e.43>

Abstract

The incidence of thyroid cancer has increased in many parts of the world and in Sri Lanka it is the second most common malignancy in females. There are several risk factors of thyroid cancer out of which exposure to radiation, genetic mutations and Hashimoto's thyroiditis are regarded as the important associations. Papillary carcinoma is the most common cancer of thyroid gland. There are several histological variants of papillary carcinoma with different biological behavior and outcome.

Aim of the study was to review the histological variants and assess the prognostic factors in a cohort of papillary carcinoma. A retrospective study done over period of 4 years in 3 specialized surgical centers. There were 91 cases of papillary carcinoma in which the histological diagnosis was reviewed and confirmed. In the study population female to male ratio was 9:1 and the mean age of papillary carcinoma was 41 years. Gross assessment showed that 89% of tumours were solid and 11% were cystic. In 29% of cases the tumour was multifocal. The most common histological types were papillary carcinoma, conventional type (24%) and the follicular variant which accounted for 35% of the cases ($p < 0.05$). Non-neoplastic thyroid tissue was within normal limits in 47 % and in 36 % there was background chronic thyroiditis. Lymph nodal involvement was seen in 22% and 6% of cases had distant metastasis.

It is important to identify the histological variants of papillary thyroid carcinoma as some of the types are associated with a poor outcome. Nodal involvement and distant metastasis showed a statistically significant association with the aggressive patterns ($p < 0.05$) of papillary carcinoma.

Keywords: Papillary thyroid carcinoma, follicular variant, papillary micro carcinoma

Introduction

Incidence of thyroid cancer has increased throughout the world ^[1, 2]. In Sri Lanka thyroid malignancy is the second most common cancer in females ^[3]. The important risk factors associated with thyroid malignancy are radiation exposure to the neck, genetic aberrations and Hashimoto's thyroiditis. Most thyroid malignancies are primary and arise from epithelial cells. The most common thyroid cancer is papillary carcinoma accounting for more than 90% of all thyroid malignancies ^[4].

The typical or conventional papillary carcinoma is a tumour exhibiting numerous papillae which could be easily recognized during the morphological assessment. The papillae are complex, may be fused and randomly oriented with a central fibrovascular core. Epithelial component lining the papillae could be confined to a single layer or stratified with cellular crowding. Papillary pattern is nearly always associated with follicle formation. Follicles are irregularly shaped and often show a tubular architecture. Distribution of the two components vary greatly from case to case. The cells of papillary carcinoma have a set of characteristic nuclear features (overlapping, moulding, ground glass appearance, pseudoinclusions and grooves) and the diagnostic confirmation of papillary carcinoma continue to be heavily dependent on the identification of these cellular details in thyroid tumours than the papillary architecture ^[5]. Psammoma bodies seen in approximately half of the cases of papillary carcinoma are also useful in supporting a diagnosis of papillary type cancer as their occurrence in other types of thyroid malignancy is exceptional. The size of papillary carcinoma ranges from few millimeters to several centimeters. The vast majority of tumours are solid and appear whitish. However, a minority of tumours can be associated with marked cystic changes.

There are several well-defined histological variants of papillary carcinoma that are encountered during the assessment of the surgical specimens of thyroid cancer ^[6].

Correspondence
Bimalka Seneviratne
Associate Professor,
Consultant Pathologist,
Department of Pathology,
Cancer Research Centre,
Faculty of Medical Sciences,
University of Sri
Jayawardenepura, Sri Lanka

Papillary microcarcinoma is defined as a tumour measuring 1 cm or less in diameter. It could be partially or completely encapsulated. Papillary microcarcinoma is reported in thyroidectomy specimens as an incidental finding. It may be associated with nodal metastasis but hematogenous spread is exceptional. Encapsulated variant is a papillary carcinoma surrounded by a fibrous capsule. The cytoarchitectural features are similar to the conventional type of papillary carcinoma. Follicular variant is a tumour completely or predominantly consisting of follicles but exhibiting the nuclear features characteristic of papillary carcinoma [7]. Few abortive papillae may be seen within the tumour. Encapsulated follicular variant may or may not be associated with capsular and / or vascular invasion but should express the nuclear features extensively. Diffuse sclerosing variant shows numerous psammoma bodies, dense sclerosis, infiltrating margins, solid areas and squamous differentiation. Oncocytic variant shows the characteristic nuclear features of papillary carcinoma along with abundant eosinophilic and granular cytoplasm. Tall cell variant shows papillae lined by tumour cells having a height at least twice the breadth. In the columnar cell variant, the papillae are lined by pseudostratified layer of tumour cells. Extremely uncommon variants include cribriform- morular type and papillary carcinoma with exuberant nodular fasciitis-like stroma [8].

Objective

Aim of the study was to review the histological variants and assess the prognostic factors in a cohort of papillary carcinoma.

Methodology

A retrospective study which included the analysis of medical records of patients who underwent thyroidectomy or lobectomy surgeries during January 2015 to December 2018, in 3 specialized centers of the Colombo district of Sri Lanka. Cases with a diagnosis of papillary carcinoma

conventional type or one of its’ histological variants were reviewed independently by two consultant pathologists prior to including in the study. There were 91 cases of papillary carcinoma in the selected cohort. Surgical specimens of the study sample have been dispatched to the laboratory immersed in an adequate volume of the formalin fixative. Following adequate fixation gross details have been documented and the specimens were serially sliced, 3-4mm apart. Representative tissue sections were submitted for routine tissue processing and staining with hematoxylin and eosin. Immunohistochemical studies have been performed in cases when the morphological features were equivocal. Information related to the prognostic outcome such as the histological type, tumour stage, histological grade and nodal status were extracted from the data records. Identification details of the participants were concealed by using a coding system.

Results

Table 1: Papillary thyroid carcinoma- Mean age & sex distribution

Papillary thyroid carcinoma	
Female: male ratio	9:1
Mean age	41 years

Papillary thyroid carcinoma is far more common in females and the mean age at presentation was 41 years.

Table 2: Papillary thyroid carcinoma - Gross findings

Papillary thyroid carcinoma	
Solid / cystic	Solid - 89% Cystic - 11%
Multifocality	Present - 29% Absent - 71 %
Tumour size	< 2 cm - 28%
	2 – 5 cm - 61%
	> 5 cm - 11%

Papillary thyroid carcinoma presented as a solid (89%) and solitary (71%) lesion in the majority of patients.

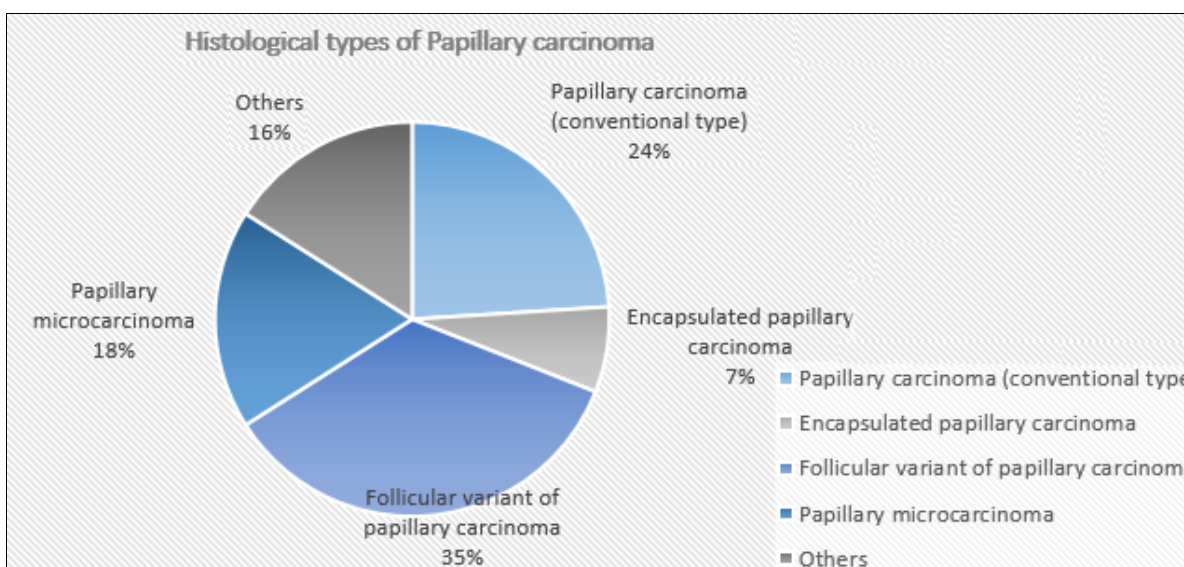


Fig 1: Papillary thyroid carcinoma - Histological types

Histological types of papillary carcinoma are shown above. Papillary carcinoma with a conventional morphology was seen in 31% of cases out of which 7% were encapsulated.

Follicular variant of papillary carcinoma accounted for 35% of the cases.

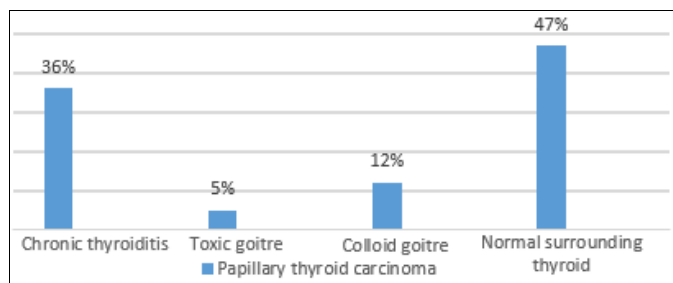


Fig 2: Papillary thyroid carcinoma-Associated pathology

In the majority of patients (47%) the background thyroid was normal. Histological findings of chronic thyroiditis were noted in 36% of the cases.

Table 3: Papillary thyroid carcinoma-Prognostic factors

Prognostic factors	Percentage (%)
Lymphovascular invasion	16%
Extrathyroid spread	11%
Nodal involvement	22%
Distant spread	6%

Lymph node deposits were seen in 22% of the cases at the time of presentation and 6% had distant metastasis.

Discussion

Papillary carcinoma is the most frequently encountered malignancy of thyroid gland. In the vast majority the disease manifests as an enlarging solitary nodule. Females were more affected than males and the mean age at the time of initial diagnosis was 41 years (table 01). Fine needle aspiration cytology technique (FNAC) is a very popular and easily available procedure widely used as a first line investigation for the assessment of diseases involving the thyroid gland. All patients in the cohort of papillary carcinoma had a cytological diagnosis which was suspicious or confirmative of a neoplastic lesion. The cytological diagnoses were confirmed by histological assessment of the thyroidectomies and lobectomy specimens of the patients. Gross evaluation had revealed that the majority of tumours were solid (89%) and uni-focal (71%) with a diameter between 2 -5 cm (table 02). In 11% of cases the tumor was > 5 cm in size. Microscopic examination revealed a spectrum of morphological changes. Papillary carcinoma with a conventional pattern was seen in 24% of the tumours. Encapsulated papillary carcinoma type was seen in 7% of tumours. These tumours had the conventional morphology with complete or near total encapsulation. Follicular variant of papillary carcinoma accounted for 35% of tumours and 18% was papillary microcarcinoma. Less frequent types together contributed to 16 % of tumours and included tall cell variant, columnar cell type, oncocyctic and sclerosing types of papillary carcinoma (figure 01).

Non-neoplastic thyroid tissue was within normal histological limits in 47% of the cases while 36% showed features of chronic thyroiditis. A small percentage of papillary carcinoma (5%) was seen in association with toxicity and in 12% of cases the background thyroid showed features of a colloid goiter (Figure 02). Spread of papillary carcinoma is usually via the lymphatics to the cervical nodes. There were 22% of cases with nodal involvement at the initial presentation. However, lymphovascular invasion

was detected only in 16% of the cases. There were 11% of cases with extrathyroid spread and 6% with distant metastasis (table 03).

Hawk WA *et al*, in their comprehensive study has also described the numerous patterns of papillary carcinoma [9]. Some of the variants were associated with an adverse outcome. Johnson TL, Lloyd RV *et al*, have described the prognostic implications of some of the aggressive types of papillary carcinoma [10]. Herrera MF *et al*, and Evans HL, have discussed the hurthle cell and columnar cell variants and the adverse behavior [11, 12]. The study done by Koo Js *et al*, has described the aggressive types of papillary carcinoma in relatively younger age group [13].

Conclusion

Review of the histological diagnoses revealed that papillary thyroid carcinoma shows a spectrum of morphological features out of which Follicular variant and conventional type being the most common ($p < 0.05$). Cervical node involvement was seen in 22% of the cases, at the time of presentation and 6% of the patients in the cohort of papillary carcinoma had distant metastasis. Some of the variants such as tall cell, columnar, diffuse sclerosing and oncocyctic are less common but, are known to be associated with an aggressive behavior. Nodal involvement and distant metastasis showed a statistically significant association with the aggressive patterns ($p < 0.05$).

During the histological examination the challenging task of the pathologist would be the identification of aggressive variants. Pathological findings which have an impact on the prognosis should be discussed at a multidisciplinary meeting before finalizing the management options. Identification of morphological features along with immunohistochemical biomarkers and molecular changes that could predict an adverse outcome would help the clinicians to select the high risk patients that require combined therapy and close follow-up.

Disclosure of conflict of interest: None.

References

1. Kilfoy BA, *et al*. International patterns and trends in thyroid cancer incidence, 1973-2002. *Cancer Cause Control*. 2009; 20:525-531.
1. Davis L. Welch HG. Increasing Incidence of Thyroid Cancer in the United States, 1973-2002. *Journal of the American Medical Association*. 2006; 295:2164-2167.
3. Cancer Incidence Data, National Cancer Control Program, Sri Lanka, 2014. nccp.health.gov.lk
4. Haymart MR. Understanding the Relationship between Age and Thyroid Cancer. *The Oncologist*. 2009; 14:216-221.
5. De Lellis RA, Lloyd RV, Heitz PU, Eng C. editors. Pathology and genetics of tumours of endocrine organs. In: Kleihues P, Sobrin LH, series editors. World health organization. Classification of Tumours. Lyon: IARC Press, 2004.
6. Kakudo K, Tang W, Ito Y, *et al*. Papillary carcinoma of the thyroid in Japan: sub classification of common type and identification of low risk group. *J Clin Pathol*. 2004; 10:1041-6.
7. Wallander M, Layfield LJ, Jarboe E, *et al*. Follicular

- variant of papillary carcinoma: reproducibility of histologic diagnosis and utility of HBME immunohistochemistry and BRAF mutational analysis as diagnostic adjuncts. *Appl. Immunohistochem. Mol Morphol.* 2010; 18:23-15.
8. Ricardo Lloyd V, Buehler D, Khanafshar E. Papillary Thyroid Carcinoma Variants. *Head and Neck Pathology.* 2011; 5(1):5-56.
 9. Hawk WA, Hazard JB. The many appearances of papillary carcinoma of the thyroid. *Cleve Clin Q.* 1976; 43:207-215.
 10. Johnson TL, Lloyd RV, Thompson NW, *et al.* Prognostic implications of the tall cell variant of papillary thyroid carcinoma. *Am J Surg Pathol.* 1988; 12:22-27. Doi: 10.1097/00000478-198801000-00003.
 11. Herrera MF, Hay ID, Wu PS, *et al.* Hurthle cell oxyphilic papillary thyroid carcinoma: a variant with more aggressive biologic behavior. *World J Surg.* 1992; 16:669-674. Doi.10.1007/BF02067351.
 12. Evans HL. Columnar-cell carcinoma of the thyroid. A report of two cases of an aggressive variant of thyroid carcinoma. *Am J Clin Pathol.* 1986; 85:77-80.
 13. Koo JS, Hong S, Park CS. Diffuse sclerosing variant is a major subtype of papillary thyroid carcinoma in the young. *Thyroid.* 2009; 19:1225-1231. doi:10.1089/thy.2009.0073.