International Journal of Clinical and Diagnostic Pathology

ISSN (P): 2617-7226
ISSN (E): 2617-7234
www.patholjournal.com
2022; 5(1): 17-21
Received: 09-11-2021
Accepted: 13-12-2021

Kedarnath V Kute
Post Graduate Student, Department of Pathology, S.R.T.R. Government Medical College, Ambajogai, Maharashtra, India

Sunil Y Swami
Associate Professor, Department of Pathology, S.R.T.R. Government Medical College, Ambajogai, Maharashtra, India

Corresponding Author:
Sunil Y Swami
Associate Professor, Department of Pathology, S.R.T.R. Government Medical College, Ambajogai, Maharashtra, India

Histopathological study of 300 breast lesions at rural tertiary care centre

Kedarnath V Kute and Sunil Y Swami

DOI: https://doi.org/10.33545/pathol.2022.v5.i1a.447

Abstract
Introduction: A breast lesion biopsy procedure is a gold standard for the diagnostic evaluation of breast lesions with primary aim to identify the cause, especially to determine whether carcinoma or premalignant lesions are present. Painful breast lump is the commonest presenting symptom in surgery out-patient department. Here, we are presenting a study of 300 breast biopsies studied histologically at rural tertiary care centre.
Objectives: This study was done to evaluate 300 breast lesion samples histopathologically at a rural tertiary care centre.
Material and Methods: A total of 300 breast biopsies were processed and H & E staining was done. Special staining and IHC was done wherever required. Histopathological correlation was done in all the cases and the results were compared to other studies.
Results: In our study of 300 breast lesions, the minimum age observed was 08 years and maximum age of 90 years with a male to female ratio of 1:18. The most common lesion in our study was benign neoplasms of breast of which fibroadenoma was predominant and observed in the age group 20-29 years followed by next common lesion as breast malignancies observed in the age group of 60-69 years.
Conclusion: Histopathological examination of breast tissue is an important tool to diagnose various breast lesions. It is important to know the histological pattern of various breast lesions in the different age group patients, as it will help to differentiate inflammatory from neoplastic lesions, benign from malignant lesions and helps in the prognosis and management of the cases.

Keywords: Breast, histopathological, inflammatory, benign, malignant, immunohistochemistry

Introduction

Breast lesions can be classified as inflammatory, epithelial and stroma proliferations, neoplasms, and developmental anomalies. Benign breast diseases are more prevalent as compared to malignant and inflammatory, as seen throughout the world. Fibroadenomas are in greater frequency among the population, constituting almost half of all cases of benign diseases. Risk factors for benign and malignant breast diseases include low parity, nulliparity, low age at first birth and late menopause, highlighting the fact towards excessive circulating oestrogen levels [1].

In the world, breast cancer is one of the commonest malignant tumours (after lung cancer) and it is the leading causes of death due to cancer in females. In India, the most common malignancy in females is breast carcinoma next to uterine cervical carcinoma. Breast cancer accounts for near one-quarter of all cancers in Indian females and about half of all cancer related mortality. With rising incidence and awareness, breast cancer is the most common cancer diagnosed in urban Indian females and the second most common in rural Indian females [2].

Breast cancer in younger patients have often been found to be associated with more aggressive behaviour, advanced disease at presentation and poorer overall survival particularly in low- and middle-income countries [3].

Aim of this study is to understand spectrum of breast lesions in our geographic area and comparison of findings with other studies.

Material and Methods

A total of 300 breast lesions were studied during a period of 3 years at a rural tertiary care centre. Inclusion criteria: Breast biopsy samples received to histopathology laboratory in the

form of Trucut biopsies, incisional biopsies and excisional biopsies like lumpectomy, simple mastectomy, modified radical mastectomy specimens were included in our study. Exclusion criteria: Inadequate biopsies, biopsies from the patients who were on treatment for malignancy and the referred patients were excluded from the present study.

The specimens received were fixed in 10% buffered formalin fixative overnight. The clinical findings from the case history and the gross findings of the specimen were noted and the biopsy tissue samples were processed routinely. Slides were stained using Haematoxylin & Eosin [H&E] and examined microscopically to arrive at a diagnosis. Special stains like Periodic Acid Schiff [PAS] stain, Gram Stain, Zeihl Neelson [ZN] stain, and immunohistochemistry [IHC] were done wherever required.

Histologically, all these breast lesions were classified into non neoplastic, benign neoplastic, and malignant breast lesions respectively. Clinicopathological correlation in all the cases were done and the results obtained were corelated with other studies.

Observations and results

A present study of 300 breast lesions, diagnosed histologically during a period of 3-years, was done at a rural tertiary care centre. Out of 300 cases, [Graph 1, Table.1] the most common breast lesions identified microscopically were benign neoplastic lesions i.e., 124 [41.3 %] followed by 115 [38.3 %] malignancies and 61 [20.3 %] non neoplastic lesions respectively and the most common age group involved was 3rd decade with a M:F ratio of 1:18.

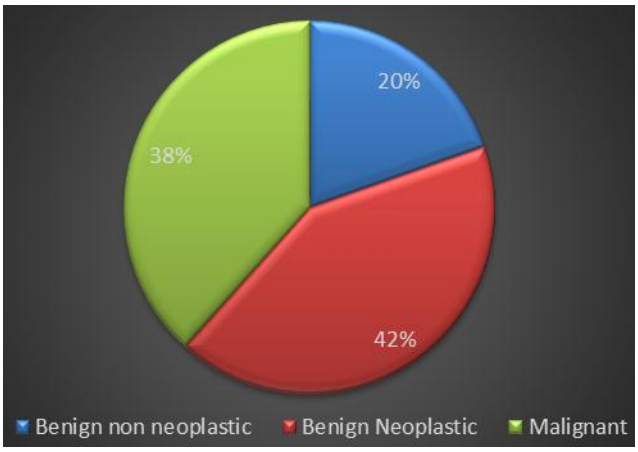

Graph 1: Showing frequency distribution of 300 breast lesions histopathologically.

Table 1: Showing age wise distribution & histological type of 300 breast lesions

Age group [Years]:	Non neoplastic	Benign	Malignant	Total
0-9	1	0	0	1
10-19	2	26	0	28
20-29	18	54	4	76
30-39	16	26	11	53
40-49	11	14	25	50
50-59	6	4	13	23
60-69	3	0	43	46
> 70	4	0	19	23
Total	61	124	115	300

Table 2: Showing frequency of histopathological lesions:

Sr. No:	Diagnosis:	No. of Cases:
1.	Inflammatory	20
2.	Ductal hyperplasia and Fibrocystic diseases	12
3.	Apocrine Cystic lesion	01
4.	Gynecomastia	11
5.	Sclerosing Adenosis	8
6.	Benign Phyllodes	5
7.	Duct Papilloma	1
8.	Fibroadenoma	111
9.	Galactocele	2
10.	Lactating Adenoma	1
11.	Adenomyoepithelioma	5
12.	Adenomyomatous adenosis	7
13.	Tubular Adenoma	1
14.	Infiltrating Duct Carcinoma: NOS	85
15.	Ductal carcinoma in situ	2
16.	Medullary Carcinoma	5
17.	Lobular Carcinoma	6
18.	Papillary Carcinoma	5
19.	Mucinous Carcinoma	5
20.	Tubular Carcinoma	1
21.	Cribriform Carcinoma	1
22.	Lymphoma	1
23.	Metaplastic Carcinoma	3
24.	Apocrine carcinoma	1
	Total Lesions:	**300**

Out of 300 breast lesions in the present study [Table.2], the most common histopathological lesion observed was fibroadenoma seen in 111 [37%] cases followed by IDC [infiltrating duct carcinoma]: NOS type seen in 85 [28.3%] cases and inflammatory breast lesions observed in 20 [6.7%] cases respectively.

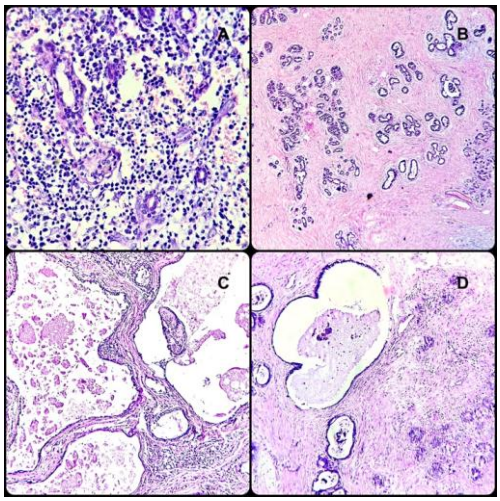

Fig 1: Showing histological features of [A]: Chronic nonspecific mastitis, [B]: Sclerosing adenosis, [C]; Galactocele and [D]: Fibrocystic disease of the breast. [H&E: 10X]

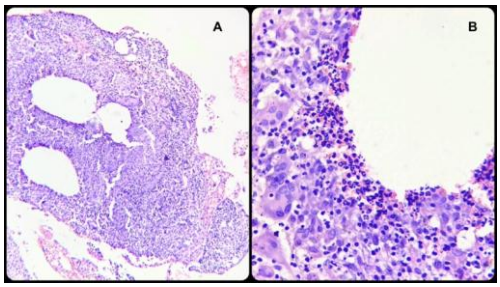

Fig 2: Cystic Neutrophilic Granulomatous Mastitis [CNGM]: Showing granulomatous mastitis with cystic spaces surrounded by plenty of neutrophils, epithelioid cells, langhans giant cells, foreign body giant cells and lymphocytes. [H&E: A:10X; B:40X]

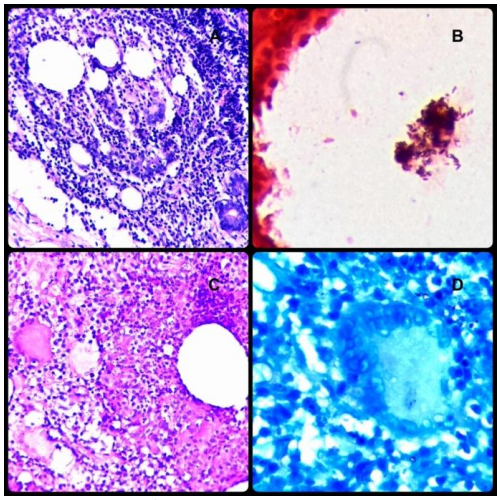

A: Granuloma formation with normal acini at the periphery. [H&E: 10X]
B: Gram positive bacilli lying in the cystic spaces. [Gram Stain: 40X]
C: Granuloma which is negative for fungus [PAS: 10X]
D: Granuloma which is negative for acid fast bacilli. [ZN stain: 40X].

Fig 3: Cystic Neutrophilic Granulomatous Mastitis [CNGM]: Showing:

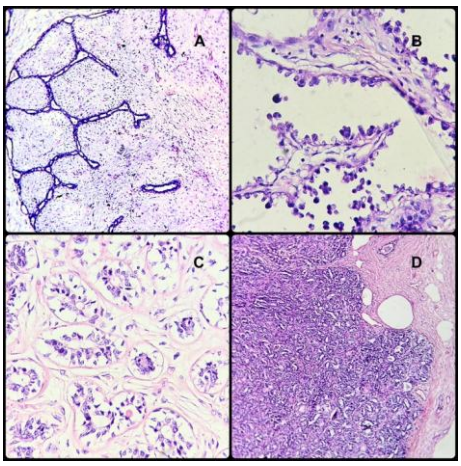

Fig 4: Showing histological features of [A]: Fibroadenoma [H&E:10X]; [B]: Lactating adenoma [H&E:40X]; [C]: Adenomyoepithelioma [H&E:40X] and [D]: Tubular adenoma. [H&E:10X]

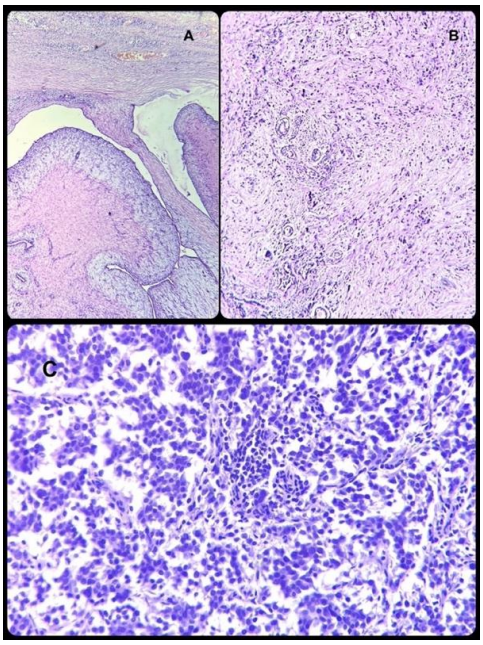

Fig 5: Showing histological features of [A]: Benign phyllodes tumor [H&E:10X]; [B]: Fibromatosis of breast [H&E:10X] and [C]: Small cell carcinoma of breast. [H&E:40X]

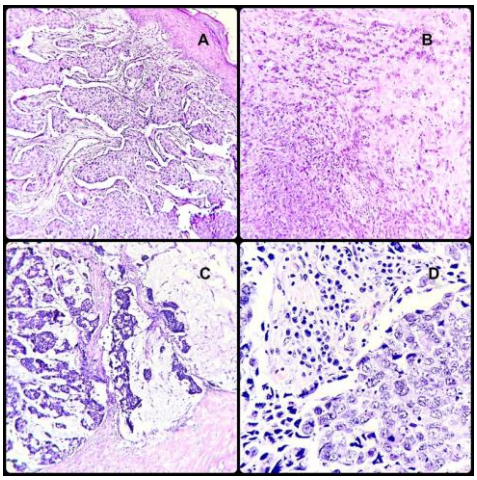

Fig 6: Showing histological features of [A]: IDC-NOS, [B]: Infiltrating lobular carcinoma, [C]: Colloid/ mucinous breast carcinoma [H&E:10X] and [D]:Mmedullary carcinoma of breast. [H&E:40X]

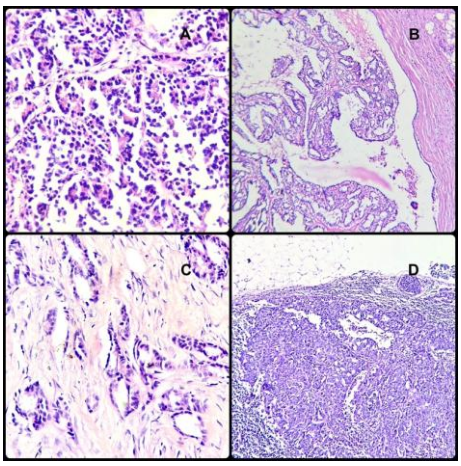

Fig 7: Showing histological features of [A]: Invasive micropapillary breast carcinoma, [B]: Papillary Carcinoma [H&E:10X], [C]: Tubular carcinoma [H&E:40X] and Lymph node metastasis of IDC. [H&E:10X]

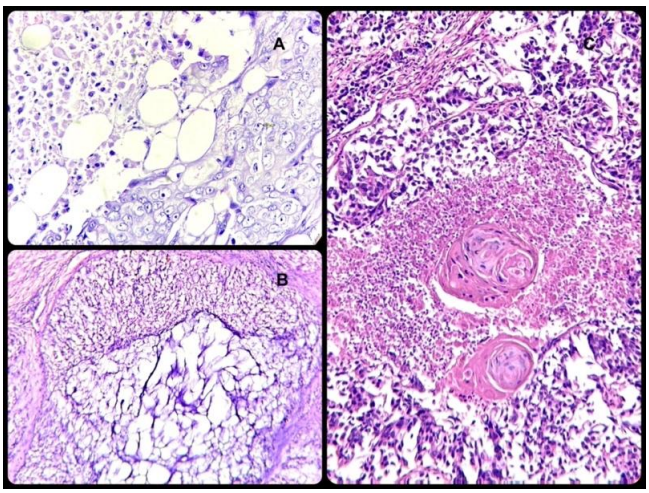

Fig 8: Showing histological features of Metaplastic carcinomas of breast [A]: with trophoblastic element, [B]: Matrix producing breast carcinoma and [C]: with squamous element. [H&E:10X]

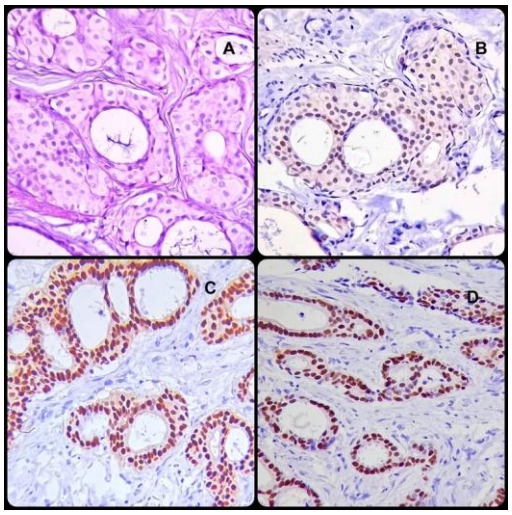

Fig 9: Apocrine breast carcinoma showing [A]: plenty of apocrine cells in groups and sheets with lumina formation [H&E:40X], [B]: mild AR positivity, [C]: strong ER positivity and PR positivity. [IHC:40X]

Table 3: Showing frequency of age wise distribution in 124 benign neoplastic lesions

Sr. No	Breast Lesions/ Age [Years]	10-19	20-29	30-39	40-49	50-59
1.	Fibroadenoma	22	51	22	13	3
2.	Duct Papilloma	0	0	0	0	1
3.	Benign Phyllodes	1	0	3	1	0
4.	Adenomyoepithelioma	1	3	1	0	0
5.	Lactating Adenoma	1	0	0	0	0
6.	Tubular Adenoma	1	0	0	0	0
Total	124	26	54	26	14	4

In the present study of 300 breast lesions [Table.3], benign neoplastic lesions were 124 [41.3%] of which, the most common lesion observed was fibroadenoma seen in 111 [37%] cases and the most common age group involved was 3rd decade.

The second common benign neoplastic lesions observed in our study were phyllodes tumours and adenomyoepitheliomas seen in 5 cases each followed by single case of duct papilloma, lactating adenoma, and tubular adenoma each.

Table 4: Showing frequency of age wise distribution in 115 breast malignancies.

Sr. No.	Malignancies/Age [Years]	20-29	30-39	40-49	50-59	60-69	>70
1.	IDC-NOS	3	8	19	9	31	15
2.	Lobular Ca	1	1	1	2	1	0
3.	Medullary Ca	0	0	2	0	3	0
4.	Papillary Ca	0	0	1	2	2	0
5.	Mucinous Ca	0	1	0	0	3	0
6.	Metaplastic Ca	0	0	0	0	1	2
7.	Apocrine Ca	0	0	0	0	0	1
8.	Tubular Ca	0	0	0	0	1	0
9.	Cribriform Ca	0	0	0	0	0	1
10	Lymphoma	0	0	0	0	1	0
11.	DCIS	0	1	1	0	0	0
12	Small cell Ca	0	0	1	0	0	0
Total	115	04	11	25	13	43	19

Out of 300 cases in our present study, malignant lesions comprised of 115 [38.3%] cases. The most common malignancy [Table.4] encountered was IDC-NOS seen in 85 [28.3%] cases which occurred with highest frequency in 7th decade.

The inflammatory lesions were seen in 20 [6.7%] cases mostly composed of chronic mastitis and breast abscesses. Out of the 16 [5.3%] cases of breast lesions encountered in males; the most common lesion was gynecomastia seen in 11 [3.7%] cases.

Discussion

Breast diseases are more prevalent among females as compared to males and the pattern of breast diseases and their aetiology varies among different countries and ethnic groups [4]. Breast lesions are detected commonly now a days due to awareness, knowledge and more importantly breast self-examination by patients.

Breast cancer accounts for one third of female cancers and nearly one fourth of all malignancies. Malignancy causes emotional distress and financial burden to the patient and their relatives. It is difficult to detect the disease in early stages and majority of patients seek medical advice when the disease has reached advanced stages [5].

Benign breast diseases are more prevalent as compared to malignant breast lesions as seen throughout the world. Out of 300 cases in the present study, 124 [41.3%] were benign neoplasms, 115 [38.3%] were malignant neoplasms and 61 [20.3%] cases were non neoplastic lesions.

Table 5: Showing comparison of most common histopathological type of breast lesions amongst benign and malignant lesions.

	Total Benign Lesions. [%]	Fibroadenoma [%]	Total Malignant Lesions. [%]	IDC- NOS. [%]
Present Study	61.7	37.0	38.3	73.9
Ghodasara *et al.* [6]	71.3	43.9	28.69	80.3
Shanthi *et al.* [7]	72	51	28	78.57
Amr *et al.* [8]	84.8	30.7	15.2	89.92
Kulkarni *et al.* [9]	80.7	62.32	19.3	84.85

In the present study [Table.5], out of 300 cases, benign breast lesions constituted 185 [61.7 %] cases including 124 [41.3%] cases of benign breast neoplasms and 61 [20.3%] cases of benign non neoplastic breast lesions. The benign lesions were more common than malignant one in the present study which is comparable to other studies. Fibroadenoma was the most common breast lesion observed amongst all the benign lesions of the breast and IDC-NOS was the most common malignancy seen amongst all the malignant lesions in the present study.

In the present study, malignancy was detected in 115 [38.3%] cases histopathologically which was comparable to study done by Srivastava *et al.* [10] Olu-eddo *et al.* [11] The ratio of benign to malignant lesions observed was 1.6:1, while it was 2.4:1 in the study done by Ghodasara *et al.* [6] Kumar M *et al.* [12] studied that in Indian rural population the benign breast diseases are 5 to 10 times more common than breast cancers and varies in different geographical areas. In our study the benign lesions were almost 1.6 times the malignant lesions. Breast lump.

In the present study, lymph node metastasis of IDC-NOS was seen in 47% of cases while the studies done by Ayadi L *et al.* [13] and Lokuhetty M *et al.* [14] documented lymph nodes metastasis in 65% and 41% respectively.

Conclusion

Most common breast lesion in our study was fibroadenoma, mostly occurring in 3rd decade of life. Malignant lesions were mostly seen after 5th decade of life. Awareness must be generated among women to reduce the morbidity and mortality with breast lesions. The clinical diagnosis of a breast lump must be correlated with histopathological diagnosis for correct and adequate treatment of patient and better prognosis.

References

1. Hafiz MA, Shafaq SH, Arshad S, Nazish S, Anum M, Ribak U. Clinico- pathological profile of patients with breast diseases. Diag Pathol. 2013;8;77:1-6.
2. Jangid P, Jangid MK, Pachori G. A histopathological study of malignant lesions of the female breast in a tertiary care centre. J Evolution Med Dent Sci. 2020;9:1795-99.
3. Jason C, Abimbola O, Neggoshane P, Cherian JC, Yoshihisa T, Vijayashree M, *et al.* Breast cancer in Jamaica: Stage, grade and molecular subtype distributions across age blocks, the implications for screening and treatment. World J Oncol. 2021;12:93-103.
4. Ghodasara NM, Dhraya C, Bhalodi J. Histopathological study of distribution of non-neoplastic and neoplastic lesions in breast. Arch Cytol Histopathol Res. 2019;4:259-64.
5. Divyasree N, Atla B, Kumar SS, Lavanya L, Reddy KS. Clinicopathological study of breast lesions over a period of one year in a tertiary care center. Int J Res Med Sci. 2018;6:3397-402.
6. Ghodasara, Dharaiya, Bhalodia. Archives Cytol Histopathol Res. 2019;4:259-64.
7. Shanthi V, Ali K, Rao NM, Krishna BR, Muralimohan KV. Clinicopathological study of breast lesions in females with assessment of correlation between tumor grade and prognostic factors and NBSP. J Biosci Tech. 2001;2:367-68.
8. Amr SS, Sadi AR, Ilahi F, Sheikh SS. The spectrum of breast diseases in Saudi Arab females: A 26-year pathological survey at Dhahran Health Center. Ann Saudi Med. 1995;15:125-32.
9. Sangeeta K, Ila MV, Kanchanmala G, Shanu SS. Histopathological spectrum of breast lesions with reference to uncommon cases. Tuberculosis. 2009;2:1-45.
10. Srivastava NK. Clinico-pathological study of 200 cases of breast lesions in a tertiary care centre of Rohtas, Bihar, India. Trop J Path Micro. 2019;5:338-42.
11. Olu-Eddo AN, Ugiagbe EE. Benign breast lesions in an African population: A 25-year histopathological review of 1864 cases. Niger Med J. 2011;52:211- 16.
12. Kumar M, Ray K, Harode S, Wagh D. The pattern of benign breast diseases in rural hospital in India. ECAJS. 2010;15:59-64.
13. Ayadi L, Khabir A, Amouri H, Karray S, Dammak A, Guermazi M. Correlation of HER-2 over-expression with clinico-pathological parameters in Tunisian breast carcinoma. World J Surg Oncol. 2008;6:112.
14. Lokuhetty MD, Ranaweera GG, Wijeratne MD, Wickramasinghe KH, Sheriffdeen AH. Profile of breast cancer in a group of women in a developing country in South Asia: Is there a difference? World J Surg. 2009;33:455-59.