



ISSN (P): 2617-7226
ISSN (E): 2617-7234
www.patholjournal.com
2021; 4(4): 163-165
Received: 27-11-2021
Accepted: 05-12-2021

Dr. Deepti KS
Assistant Professor,
Department of Pathology,
Srinivas Institute of Medical
Sciences, Mangalore,
Karnataka, India

Dr. Narendr KL
Assistant Professor,
Department of Pathology,
Srinivas Institute of Medical
Sciences, Mangalore,
Karnataka, India

Histological changes of placenta in normal and high risk pregnancies and effect of pregnancy outcome

Dr. Deepti KS and Dr. Narendr KL

DOI: <https://doi.org/10.33545/pathol.2021.v4.i4c.438>

Abstract

Background: High risk pregnancies are a small segment of the obstetric population, that produces the majority of maternal and infant mortality and morbidity. Upto 40% of high risk mothers experience placental damage. The pathological changes in the Placenta are not by large specific to a particular disorder and therefore a variety of disorders may show similar changes. This study is an attempt has been made to correlate various placental villous changes to the fetal outcome in normal and specific high risk pregnancies. This study was done in Department of Pathology, Srinivas Institute of Medical Sciences, Mangalore. The study was done from Oct 2017 to March 2019.

Keywords: Morphological, histo-pathological, placenta, normal, high risk

Introduction

High risk pregnancies are a small segment of the obstetric population that produces the majority of maternal and infant mortality and morbidity. Upto 40% of high risk mothers experience placental damage. The pathological changes in the Placenta are not by large specific to a particular disorder and therefore a variety of disorders may show similar changes. This study is an attempt has been made to correlate various placental villous changes to the fetal outcome in normal and specific high risk pregnancies. Placenta is a vital lifeline between mother and fetus through which nutrients, oxygen, antibodies and hormones pass^[1, 2, 3]. Improper placentation and placental function could be potentially danger to the health of the mother and the fetus^[4, 5]. High risk pregnancies are a small segment of the obstetric population that produces the majority of maternal and infant mortality and morbidity^[6-9]. Upto 40% of high risk mothers experience placental damage. The pathological changes in the Placenta are not by large specific to a particular disorder and therefore a variety of disorders may show similar changes^[10, 11]. Final picture is often very complicated and no particular complication of pregnancy produces specific morphological changes within the placenta, which allow one to make a specific morphological diagnosis^[12]. In this study, an attempt has been made to correlate histology changes to fetal outcome in normal and specific high risk pregnancies.

Aims and Objectives

To study the histological changes of placenta in normal and high risk pregnancies and effect of pregnancy outcome

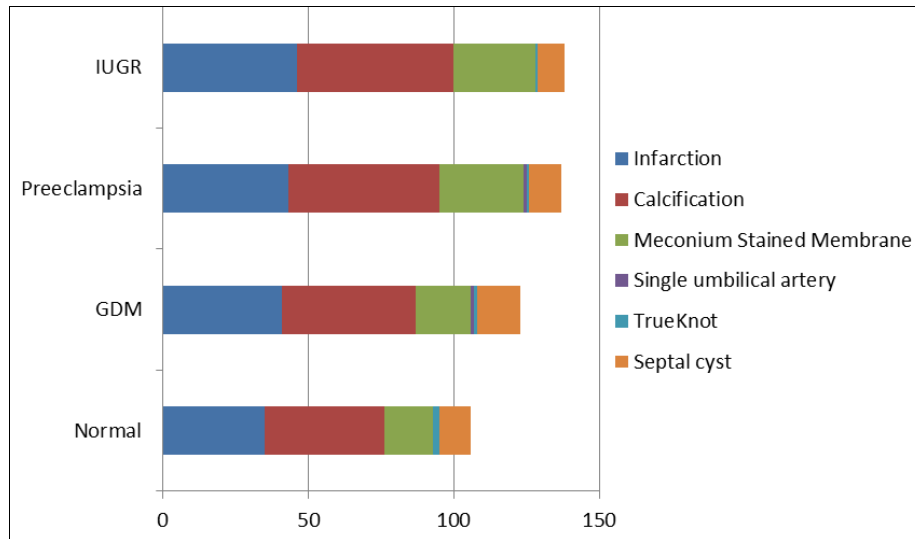
Materials and Methods:

This study is an attempt has been made to correlate various placental villous changes to the fetal outcome in normal and specific high risk pregnancies. This study was done in Department of Pathology, Srinivas Institute of Medical Sciences, Mangalore. The study was done from Oct 2017 to March 2019.

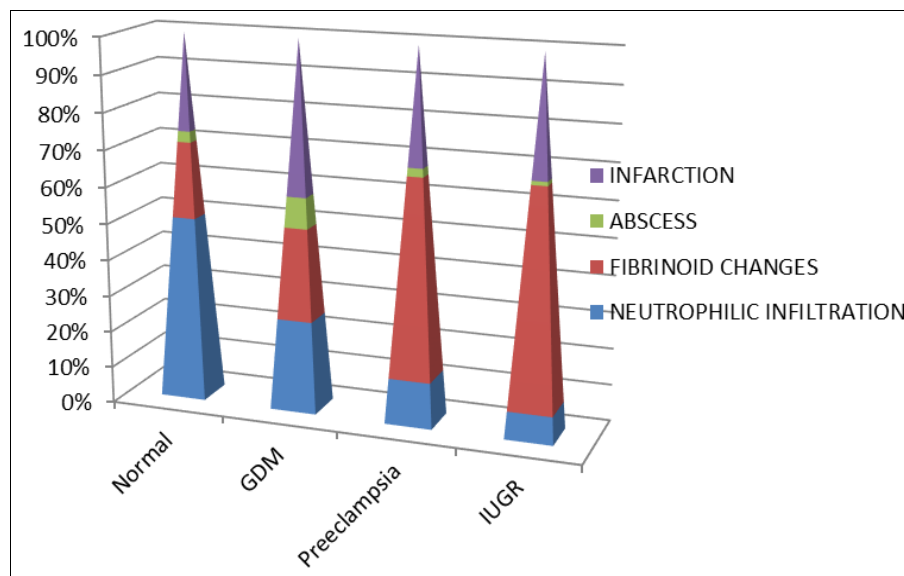
It is a prospective study of morphology and histology of placenta in randomly selected normal and specific high risk pregnancies and its correlation with fetal outcome. The study was done in 90 patients. The placenta was dipped in 10% formalin solution for fixation for a period of 48 hrs. They were then cut at every 2 cm interval into vertical strips. 5 μ thin sections were cut from each block and stained with haematoxylin and eosin. Two bits from cord were taken. Each section from placenta was examined with light microscope.

Corresponding Author:
Dr. Narendr KL
Assistant Professor,
Department of Pathology,
Srinivas Institute of Medical
Sciences, Mangalore,
Karnataka, India

Results



Graph 1: Macroscopic features of placenta



Graph 2: Histological features

Outcome

- There was no significant correlation with calcification, other morphological features such as both the type of placenta, septal cyst, true knot, with fetal outcome.
- Neonatal mortality was observed in the 1st week of delivery in cases where we see such histomorphological changes of placenta.

Discussion

This study is an attempt has been made to correlate various placental villous changes to the fetal outcome in normal and specific high risk pregnancies. This study was done in Department of Pathology, Srinivas Institute of Medical Sciences, Mangalore. The study was done from Oct 2017 to March 2019. It is a prospective study of morphology and histology of placenta in randomly selected normal and specific high risk pregnancies and its correlation with fetal outcome. Placental pathologic examinations are pointless if they do not provide clinically useful data. One important limitation of placental examination is the inability to make a one to one link between any one placental and uteroplacental vascular lesion and a particular maternal or

fetal, neonatal problem. This would be an unrealistic goal, because in no other organs are such relationship the rule. Neither hepatocellular necrosis nor glomerulosclerosis for example, is diagnostic of one and only one hepatic or renal disease; in those diseases individual lesions are considered as part of a greater histopathologic pattern. Finally the pattern is correlated with a variety of clinical data, laboratory data, and additional pathologic studies to produce the final clinical pathologic diagnosis. Through examination of the delivered placenta can provide a better picture of the intrauterine environment of the fetoplacental unit than a placental bed biopsy. The ability to routinely identify failure of uteroplacental vascular adaptation, fibrinoid necrosis, atherosclerosis, persistence of endovascular trophoblasts, thrombosis and chronic vasculitis in the basal plate can clarify the nature and mechanisms involved in pregnancy compromise. Many studies are upcoming for placenta screening for high risk pregnancies by using a combination of ultrasound and blood tests to screen high risk pregnant mothers for placental damage. By completing these non-invasive tests, most high risk mothers can be reassured that their placenta is formed and functioning properly, so they

can expect a healthy pregnancy. This is an important first step in identifying placental abnormalities in early pregnancy, at a time when a number of interventions can be used to improve outcomes for those with the highest risk. This study will lead the way for future research in placenta screening and help us provide quality care for all mothers.

Conclusion

Many studies are upcoming for placenta screening for high risk pregnancies by using a combination of ultrasound and blood tests to screen high risk pregnant mothers for placental damage. By completing these non-invasive tests, most high risk mothers can be reassured that their placenta is formed and functioning properly, so they can expect a healthy pregnancy.

References

1. Benirschke K, Kaufmann. The pathology of maternal floor infarction. In pathology of human placenta. New York NY - Springer verlage Inc. 1990;406:411.
2. Benirschke K, Kaufmann P. Pathology of human placenta 3rd edition. Springer Verlag New York. 1995.
3. Chrolyn, Chandler. Placental pathology in perinatal diagnosis in Gynecology and Obstetrics. J.B. Lippincott company. Philadelphia. E/dy^r John J. MD. Ph.D. Ch-106. 1992;31:1-39.
4. Caspi Soloman, Amnionitis F, Strainmycoplasma T. Am. J. Obstet Gynecol. Ill. 1971, 1102.
5. Cynthia G, Kaplan Carolyn Salafia. College of American Pathologists. Conference XIX on examination of placenta. Report of working group on the def of structural changes associated with abnormal functions in maternal / fetal placental unit in 2nd and 3rd trimester. Arch. Pathol. Lab. med. 1991;115:709-716.
6. Driscoll SG. Pathology of placenta in intrauterine growth retardation. Ann. Chir, Gynaecol. 1987;70:316.
7. Daskalakis G, Marinapoulas Krielesiv, Papapanagiotou A. Placental pathology in women with gestational diabetes. Acta Gynecol Scand. 2008;87(4):403-7.
8. Ethches PC. Stewart. The relationship between disorders of umbilical cord and intrauterine growth retardation. Acta. Obstot, Gynecol scand. 1982;72:15.
9. Fox H. Pathology of placenta, London. WB Souder Ltd., 1978. Fox, H. Thrombosis of fetal arteries in human placenta, BJOG. 1966;73:961-965.
10. Fox H. General pathology of placenta in Fox, H. ed: Obstetrical and Gynecological pathology New York NY: Churchill Linnstone, Inc Z. 1987;972:1000.
11. Geoffrey Altshuler. Scott - R - clinicopathological implications of placental pathology clinical obstet and Gynaecol. 1996;29:549-570.
12. Gruenwal P (Ed). The placenta and its maternal supply Line. Lancaster, medical and technical publishing. 1975.
13. Hans G. Kohler Pathology of Umbilical cord and fetal membranes in Hainee M. Obstetrical and gynecological. Path. 1987;2:1079-1116.
14. Haust MD. Maternal Diabetes mellitus - effects on the Fetus and placenta, Ch.8. In Naeye Kissane, JM (eds). Prenatal disease, Williams or Wilkins. 1981.