



ISSN (P): 2617-7226
ISSN (E): 2617-7234
www.patholjournal.com
2018; 1(1): 21-25
Received: 12-11-2018
Accepted: 14-12-2018

Dr. Ganga H

Assistant Professor, Subbaiah
Institute of Medical Sciences,
Shivamogga, Karnataka, India

Dr. Indudhara PB

Associate Professor, Subbaiah
Institute of Medical Sciences,
Shivamogga, Karnataka, India

Histopathological spectrum of lesions of upper gastrointestinal tract: A study of endoscopic biopsies

Dr. Ganga H and Dr. Indudhara PB

DOI: <https://doi.org/10.33545/pathol.2018.v1.i2a.06>

Abstract

Background: Upper gastrointestinal tract disorders are one of the most commonly encountered problems in clinical practice. A variety of disorders can affect the upper GIT. The definitive diagnosis of upper gastrointestinal disorders rests on the histopathological confirmation and is one of the bases for planning proper treatment.

Aims and objectives: To determine the spectrum of histopathological lesions of upper gastrointestinal tract and to establish endoscopic biopsies as an effective tool in the proper diagnosis and management of various upper gastrointestinal tract lesions.

Materials and Methods: A prospective study was conducted on the upper GIT endoscopic biopsies and the histopathological assessment was done at the department of pathology, Subbaiah institute of medical sciences, Shimoga from July 2016 to July 2017.

Results: A total of 144 cases were taken and 163 endoscopic biopsies were studied. There were 88 male patient and 56 female patients. An age range of 9-88years was observed. There were 30 (18.4%) cases from esophagus, 05(3.06%) cases from GE junction, 93(57.05%) cases from stomach, 1 case (0.61) from neo stomach (GJstoma) and 34(20.85%) cases from duodenum. 100(61.34%) cases were non-neoplastic, 33(20.24%) cases were benign neoplasms while 30(18.40%) were malignant neoplasms. Histopathology revealed gastritis 63cases (63%) as the most frequently diagnosed inflammatory lesion while squamous cell carcinoma of esophagus, 19 cases (63.33%) comprised the most frequently diagnosed malignant lesion.

Conclusion: In our study, the commonest site for upper GI endoscopic biopsy was from the stomach (57%) with 69.89% non neoplastic and 31.18% neoplastic lesions. Most common neoplasm of the stomach was adenocarcinoma. Endoscopy generates biopsy specimens from sites that were previously inaccessible without a major resection. So a thorough knowledge of the spectrum of lesions that can be diagnosed in these specimens is pertinent to make a proper diagnosis for better patient management.

Keywords: Upper GIT, endoscopy, biopsy, histopathology

Introduction

Upper GI disorders are one of the most commonly encountered problems in clinical practice with high degree of morbidity and mortality. Various pathology involving the upper Gastro intestinal tract manifest with a similar group of symptoms which are difficult to assess clinically. There are several diagnostic investigations available in the evaluation of these symptoms where endoscopy is performed as the initial diagnostic test ^[1].

The upper gastrointestinal flexible fiber optic endoscope was first used in 1968 and was a major breakthrough in the diagnosis of gastrointestinal tract (GIT) lesions ^[2]. Currently Upper GIT endoscopy is regarded as an established modality of investigation as well as treatment for most patients with upper GI symptoms ^[3]. It is a simple, safe and well tolerated procedure with direct visualization of the pathologic site. The major indications for upper GIT endoscopic biopsy include evaluation of dyspepsia, odynophagia, dysplasia, peptic ulcer disease, infections, inflammatory disorders, vascular disorders, mechanical conditions, toxic and physical reactions, including radiation injury and neoplasms. It generates biopsies from the sites that were previously inaccessible, without the major resection. Biopsies are taken to establish a specific diagnosis or to follow the evolution of a particular lesion or disease. It also helps to determine the extent and severity of a disease, to determine the response to therapy and to detect cancers or their premalignant stages. Endoscopic practice is undergoing a revolution with the development of much more accurate video-endoscopy, magnifying endoscopy and techniques such as chromo-endoscopy, autofluorescence imaging and narrow band imaging ^[4].

Correspondence

Dr. Indudhara PB

Associate Professor, Subbaiah
Institute of Medical Sciences,
Shivamogga, Karnataka, India

Upper gastrointestinal tract is one of the most common sites for neoplasms, especially malignant tumours. Worldwide, gastric adenocarcinoma is the second most common cancer and carcinoma oesophagus is the sixth leading cause of death.

Aims and Objectives

- To determine the spectrum of histopathological lesions of upper gastrointestinal tract.
- To establish endoscopic biopsies as an effective tool in the proper diagnosis and management of various upper gastrointestinal tract lesions.

Materials and Methods

A prospective study was conducted on the upper GIT endoscopic biopsies from July 2016 to July 2017 at the department of pathology, Subbaiah institute of medical sciences, Shimoga. Patients of all ages and both sexes with upper GI symptoms who underwent endoscopic examination and biopsies were taken. Specimens were fixed in 10% of formalin and were routinely processed and examined with H&E stain. Special stains like PAS and Giemsa’s stains were used wherever necessary.

Inclusion criteria

- All the endoscopic biopsies of upper GI tract

Exclusion criteria

- All the lesions of mouth and pharynx
- All the duodenal biopsies beyond 2nd part of duodenum.

Results

- A total of 144 cases were taken and 163 endoscopic biopsies were studied. There were 88 male patient and 56 female patients with male female ratio being 1.57: 1.
- An age range of 9-88years was observed. Majority of the cases were in 4th and 5th decade. Youngest patient was 9 yr old male with celiac disease and oldest patient was 88 year old male with squamous cell carcinoma esophagus.

Site wise distribution of endoscopic biopsies was- Oesophagus 30 cases (18.4%), Stomach 93 cases (57.05%), duodenum 34 cases (20.85%), GE junction 05 cases (3.06%), Neostomach 1 case (0.61)

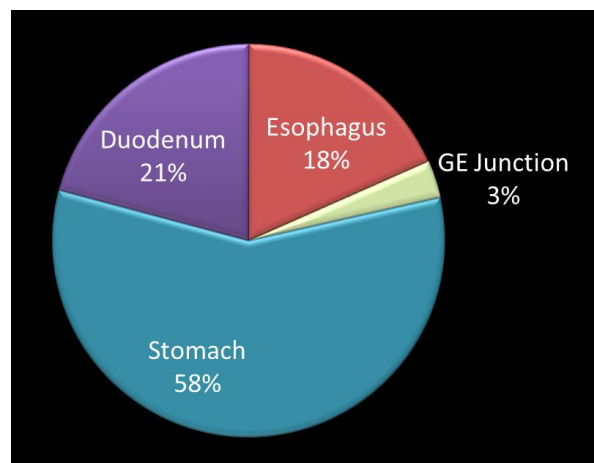


Fig 1: Site distribution of upper GI biopsies

On histology assessment, a total number of diagnosed malignant cases were 30. Most of which were from esophagus 19 cases (63.33%), followed by stomach 7 cases (23.33%), duodenum 2 cases (6.66%) and OGI 2 cases (6.66%).

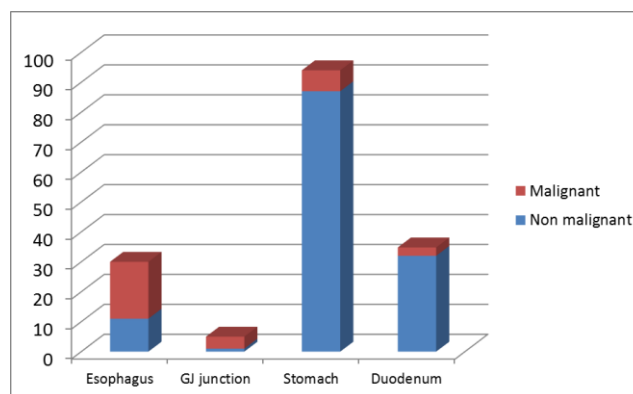


Fig 2: Histopathological spectrum of upper GI lesions

Out of 30 esophageal biopsies, 19 cases (63.33%) showed squamous cell carcinoma. chronic non-specific esophagitis was seen in 3 cases (10%), There were 2 cases (6.66%) of low grade dysplasia, 3 cases(10%) of high grade dysplasia, 1 case (3.33%) of dysplasia associated with Barret’s esophagus and 2 cases (6.66%) of Barret’s esophagus.

Table 1: Site wise distribution of lesions of esophagus

	Upper esophagus	Middle esophagus	Lower esophagus
Inflamartory lesions	-	3	-
Malignancy	5	8	6
Low grade dysplasia	-	2	-
High grade dysplasia	-	3	-
Dysplasia associated Barret esophagus	-	-	1
Barret esophagus	-	-	2

All the malignant neoplastic lesions of esophagus were squamous cell carcinoma on morphology with 11 (57.8%) patients being males and 08 (42.1%) patients being females. Majority of the lesions were found in middle esophagus 8 cases (42.1%) followed by lower esophagus 6 cases

(31.57%) and upper esophagus 5 cases (26.31%). On histopathological grading, 12 cases (63.15%) cases were moderately differentiated, 5 (26.31%) were well differentiated and 2 (10.52%) were poorly differentiated.

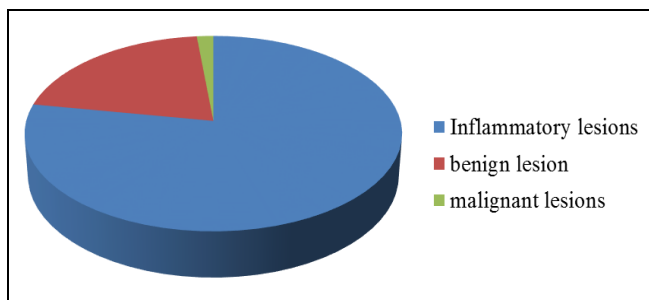


Fig 3: Histopathological spectrum of lesions of stomach (93 cases)

Table 2: Site wise distribution of lesions of stomach

Location	No of cases (93 cases)	Percentage
Fundus and cardia	08	8.6%
Body	22	23.5%
Pylorus and antrum	63	67.7%

Table 3: Inflammatory lesions of stomach

Lesion	No of cases (68 cases)	Percentage
Acute non-specific gastritis	05	7.3%
Gastric ulcer	02	2.9%
Chronic non-specific gastritis	25	36.7%
Chronic gastritis with H pylori	29	42.6%
Chronic gastritis with intestinal metaplasia	04	5.8%
Chronic gastritis with low grade dysplasia	03	4.4%

Out of 61 cases of chronic gastritis, 29 (47.54%) cases showed H. pylori infection. Most of the lesions were from antrum 21(72.4%) cases and 8 (27.5%) were from body of stomach. In most of the H pylori associated gastritis, neutrophilic inflammatory cells (activity) was noted in 22 cases (75.86%) while 7 (24.13%) cases showed mixed inflammation.

There were 18 cases of benign lesions of stomach. Out of which 14 (77.7%) were hyperplastic polyp and 4 (22.2%) were fundic gland polyp

Table 4: Endoscopic findings in malignant lesions of stomach

Endoscopic findings	No of cases(7 cases)	Percentage
Ulcerative growth	2	28.5%
Ulceroproliferative	3	42.8%
Flattening of mucosa	1	14.2%
Erythematous appearance	1	14.2%

There were 7 malignant lesions of stomach. Out of which 5 (71.4%) were intestinal type of adenocarcinoma (3 of them were moderately differentiated, 1 was poorly differentiated and 1 was well differentiated.)

There were 2 (28.5%) cases of diffuse adenocarcinoma. Site wise distribution showed 5 (71.4%) cases from antrum and 2

(28.5%) cases from body of stomach.

Out 5 biopsies from GE junction, 3 cases (60%) showed adenocarcinoma, 1 case (20%) of low grade dysplasia and 1 case (20%) of Barret’s esophagus.

Table 5: Lesions of Duodenum

Lesions	No of cases (34 cases)	Percentage
Chronic non-specific duodenitis	18	52.9%
Chronic duodenitis with H pylori	06	17.6%
Celiac disease	02	5.8%
Hyperplastic polyp	04	11.7%
Tubular adenoma	01	5.5%
Malignant lesions	03	8.8%

Out of 3 malignant lesions of duodenum 2 cases showed adenocarcinoma and 1 case was carcinoid.

And 1 case from neo stomach showing post radio/chemotherapeutic changes.

Discussion

Gastric and esophageal cancers are the most common cancers found in men. While esophageal cancers rank 3rd among women after breast and cervical cancer [5]. Histopathological study of endoscopic biopsies are used to confirm the diagnosis in suspected malignant cases or to make diagnosis of benign condition, thus helping in early therapeutic decision. The incidence of gastro intestinal malignancies increases with age which has led to increased number of endoscopy as well as biopsy in order to detect cases at the earliest stage [6] Even the slightest clinical suspicion at middle and old age warrants the endoscopic biopsy and histopathological analysis.

In the present study the most of the patients undergoing Endoscopic biopsy were in the age group between 41 and 50 years. Patients undergoing Endoscopic biopsies were predominantly males in the present study with male to female ratio of 1.57: 1 which was also observed in other studies done by Sandhya PG *et al.*, [7] Rashmi K *et al.* [3] and Shennak MM *et al.* [8] The gender ratio favoring males could be because of fact that males are exposed to more risk factors than female and gastrointestinal malignancies are more common in male.

In our study the most common site from which the biopsies were taken was stomach followed by duodenum and esophagus similar to the studies conducted by Jaynul Islam SM *et al.* [7], Sandhya PG *et al.*, [7] Memon F *et al.*, [7] Krishnappa R *et al.*, [3] and Hirachand *et al.* [8]

Majority of the lesions of upper GIT were non-neoplastic in the present study which in consensus with study by Gulia SP *et al.* [12] and Kothari SL *et al.* [13]

Among 30 malignant lesions, esophagus was the most common site (63.33%) in the present study which was similar to study by Rao DN *et al.* [14]

Table 6: Comparison of malignant lesion of esophagus with site.

	Upper esophagus	Middle esophagus	Lower esophagus
Present study	26.3%	42.1%	31.5%
Krishnappa <i>et al.</i> [3]	9%	73%	18%
Sheik <i>et al.</i> [15]	4.87%	26.8%	68.3%

Gastric lesions constituted the majority of the cases. Out of 93 gastric biopsies, 68 were inflammatory lesions which was similar to Krishnappa *et al.* [3] and sheik *et al.* [14]. Among the inflammatory lesions of the stomach, chronic gastritis with H pylori was common in the present study.

Table 7: Comparison of H pylori associated changes

	Neutrophilic activity	Intestinal metaplasia	Glandular atrophy
Present study	75.86%	13.7%	6.89%
Hussain <i>et al.</i> [16]	87.5%	31.25%	68.7%
Ohkuma <i>et al.</i> [17]	100%	32.5%	39.2%

Out of 93 stomach biopsies, 7 were malignant lesions. Intestinal type of adenocarcinoma was seen in 5 cases (71.45) and 2 cases (28.3%) showed diffuse carcinoma which was similar to study by Krishnappa *et al.* [3] and sheik *et al.* [15]

Table 8: Comparison of site wise distribution of gastric cancer

Site	Present study	Krishnappa <i>et al.</i> [3]	Sheik <i>et al.</i> [15]
Pylorus with Antrum	71.7%	43%	53.3%
Body	28.3%	26%	26.6%
Fundus and cardia	-	5%	13.3%

Out of 5 lesions of GE junction 3 cases (60%) showed adenocarcinoma, this finding correlates with Rumana *et al.* [18] and sheik *et al.* [15].

There were 34 endoscopic biopsies available for histopathological examination of first two parts of duodenum. Most of the cases were non-specific duodenitis similar to Krishnappa *et al.* [3]. Incidence of other lesions were similar to sheik *et al.* [15].

Conclusion

Biopsy sampling of upper gastrointestinal mucosa at diagnostic endoscopy provides useful information. A variety of non - neoplastic and neoplastic lesions were reported.

In our study, the commonest site for upper endoscopic biopsy was from the stomach (58%) with 92% non-neoplastic and 08% neoplastic lesions. Chronic gastritis with H pylori being most common inflammatory lesion of stomach and intestinal type of adenocarcinoma being most common malignant lesion. The second most common site was duodenum with chronic non-specific duodenitis was frequently diagnosed. Among the esophageal biopsies studied squamous cell carcinoma was frequently diagnosed and accounted for most common malignant lesions in the present.

Limitations in diagnostic interpretation are encountered at times due to tiny biopsy material, handling and processing artefacts. However, multiple bits of endoscopic biopsies from abnormal looking mucosa are recommended to establish a definitive diagnosis. Whenever there was a disagreement, the histopathological appearances served to correct a mistaken endoscopic finding. We therefore conclude that endoscopy is incomplete without biopsy and so the combination of methods provides a powerful diagnostic tool for better patient management study.

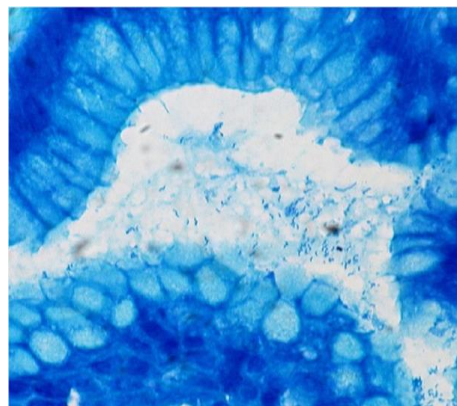


Fig 4: Photomicrograph of Helicobacter Pylori organisms (Giemsa stain 100X)

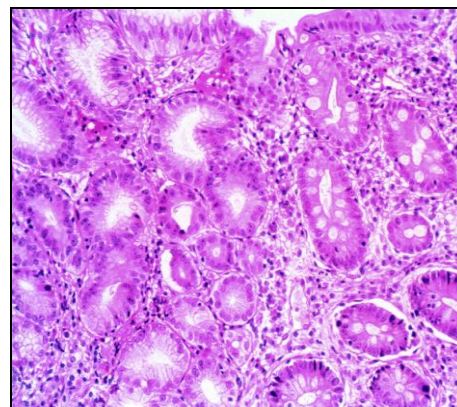


Fig 5: Chronic gastritis with intestinal metaplasia (H& E, 40X)

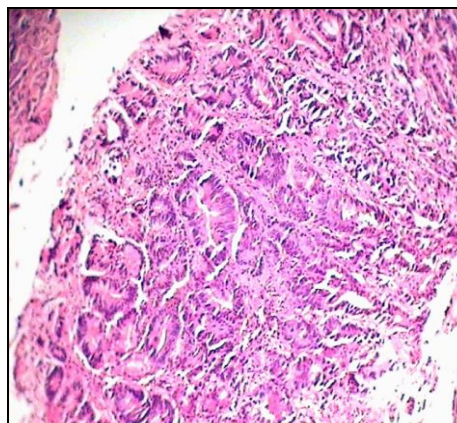


Fig 6: Histopathology showing well differentiated adenocarcinoma of stomach. (H&E10X).

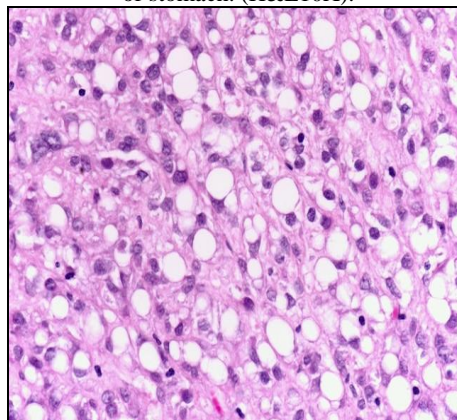


Fig 7: Signet ring adenocarcinoma stomach (H&E, 40X)

References

1. Varadarajulu S, Eloubeidi MA, Patel RS, Mulcahy HE, Barkun A, Jowell P *et al.* The yield and the predictors of esophageal pathology when upper endoscopy is used for the initial evaluation of dysphagia. *Gastrointest Endosc.* 2005; 61(7):804-8.
2. Black stone MO. Endoscopic interpretation normal and pathologic appearance of the gastrointestinal tract. New York: Raven Press, 1984, 13-15.
3. Rashmi K, Horakerappa MS, Karar A, Mangala G. A study on histopathologic spectrum of upper gastrointestinal tract endoscopic biopsies. *Int J Medical Res Health Sciences.* 2013; 2(3):418-24.
4. Shepherd NA, Valori RM. The effective use of gastrointestinal histopathology: guidance for endoscopic biopsy in the gastrointestinal tract. *Frontline gastroenterology.* 2014; 5:84-7.
5. Somani NS, Patil P. Histopathological Study of The Upper Gastrointestinal Tract Endoscopic Biopsies. *Annals of Pathology and Laboratory Medicine.* 2018; 5(8):A-644-88.
6. Sandhya PG, Madhusudan C, Naseem N, Balkrishnan CD, Balagurunathan K. Interpretation of upper gastrointestinal tract endoscopic mucosal biopsies- A study conducted in teaching hospital in Punducherry, India. s.l. *International Journal of Medical and Health Sciences.* 2012; 1(3):17-24.
7. Shennak MM, Tarawneh MS, Al Sheik. Upper gastrointestinal diseases in symptomatic Jordanians: A prospective study. *Ann Saudi Med.* 1997; 17(4):471-4.
8. Jaynul Islam SM, Mostaque Ahmed ASM, Uddin Ahamad MS, Hafiz SAMMA. Endoscopic and histologic diagnosis of upper gastrointestinal lesions, experience in a Port City of Bangladesh. *Chattagram Maa-o-Shishu Hospital Medical College Journal.* 2014; 13(3):11-4.
9. Memon F, Baloch K, Memon AA. Upper gastrointestinal endoscopic biopsy; morphological spectrum of lesions. *Professional Med J.* 2015; 22(12):1574-9.
10. Hirachand S, Sthapit RR, Gurung P, Pradhanang S, Thapa R, Sedhai M *et al.* Histopathological spectrum of upper gastrointestinal endoscopic biopsies. *JBPKIHS.* 2018; 1(1):68-7.
11. Gulia SP, Chaudhury M, Noorunnisa N, Balakrishnan CD, Balagurunathan K. Interpretation of Upper Gastro Intestinal Tract Endoscopic Mucosal Biopsies – A Study Conducted in Teaching Hospital In Puducherry, India. *Int J Med Health Sci.* 2012; 1(3):17.
12. Kothari SL, Dayal A, Patel SM. Interpretation of Upper Gastrointestinal Tract Mucosal Biopsies – A Tertiary Care Centre Experience. *Annals of Pathology and Laboratory Medicine.* 2018; 5(8):A-709-14.
13. Rao DN, Desai PB, Ganesh B. Epidemiological observation of cancer of the esophagus- A review of Indian studies. *Indian J of cancer* 1996; 33:55-75.
14. Sheik BA, Hamdani MS, Malik R. Histopathological spectrum of lesions of gastrointestinal tract- A study of endoscopic biopsies. *GJMEDPH* 2015; 4(4).
15. Hussain IS, Reshi R, Akther G, Beigh A. clinicohistopathological study of upper gastrointestinal tract endoscopic biopsies: *Int J Cur Res Rev,* 2015; 7(16).
16. Ohkuma K, Okada M, Murayama H *et al.* Association of H pylori infection with atrophic gastritis and intestinal metaplasia. *J Gastroenterol Hepatol,* 2000; 15(10):1105-12.
17. Rumana M, Khan AR, Khurshid N *et al.* The changing pattern of esophageal gastric cancer in kashmir. *JK practioner international.* 2005; 12(4):189-92.
18. Abilash SC, Kolakkadan H, Gitanjali MM, Shreelakshmidivi S, Balamuruganvelu S. Histopathologic Spectrum of Upper Gastrointestinal Tract Mucosal Biopsies: A Retrospective Study. *Sch. J. App. Med. Sci.* 2016; 4(5E):1807-13.
19. Rajesh kumar G, Bano B, Kapoor B *et al.* Clinical profile in H pylori positive patients in Jammu, s.l: *JK science.* 2006; 8(3):148-50.