



ISSN (P): 2617-7226
ISSN (E): 2617-7234
www.patholjournal.com
2019; 2(1): 152-160
Received: 04-11-2018
Accepted: 07-12-2018

Dr. Srinivas DD Gubbala
Associate Professor,
Department of Pathology,
Kamineni Institute of Medical
Sciences, Sreepuram,
Nalgonda, Narketpalli,
Telangana, India

Dr. Sridevi Mattaparti
Assistant Professor
Department of Pathology
Kamineni Institute of Medical
Sciences, Sreepuram,
Nalgonda, Narketpalli,
Telangana, India

Clinico-pathological analysis and re-evaluation of role of testicular biopsy in male factor infertility: A prospective study and review of literature

Dr. Srinivas DD Gubbala and Dr. Sridevi Mattaparti

DOI: <https://doi.org/10.33545/pathol.2019.v2.i1c.23>

Abstract

Context: For many years Testicular biopsy was considered the gold standard for diagnosis in men with unexplained infertility. However recent guidelines have limited the indications for a diagnostic testicular biopsy and there is paradigm shift towards prognostic and therapeutic significance.

Aims

1. To re-evaluate the role of testicular biopsy in male factor infertility and guide in planning the management protocols.
2. To identify potential candidates who would benefit from assisted reproductive techniques.

Settings and Design: The present study was conducted at the Department of pathology, Kamineni Institute of Medical Sciences, Narketpally over a period of 3 years, starting from June 2015 to June 2018. This study was a prospective study.

Material and Methods: This study involved schematic evaluation of cases with male infertility which included clinical history, physical examination, semen analysis, hormone analysis, radiological evaluation (Scrotal and trans-rectal Ultrasonography) for obstructive etiology and finally testicular biopsy. Histomorphology of Testicular biopsy specimens were analyzed and the results were documented.

Statistical analysis used: Simple percentages and Graphical representation of the data.

Results: Testicular biopsy done in 71 patients revealed Hypo-spermatogenesis as the most common histological finding. Second most common abnormality reported was Sertoli cell only syndrome/Germ cell aplasia. Majority of cases of Varicocele, inguinal hernia and radiologically documented obstructive cases revealed normal spermatogenesis. And using microsurgical assisted reproduction techniques, sperms were retrieved from all cases of Hypo-spermatogenesis. Sperm retrieval rates were 70% and 31.3% in maturation arrest and Sertoli cell only syndrome respectively.

Conclusions: Testicular biopsy in the management of Male factor infertility carries prognostic significance. In patients with obstructive azoospermia, presence of normal spermatogenesis and hypo-spermatogenesis carries good prognosis as surgical repair of the defects recovers fertility in majority of cases. In cases with non-obstructive azoospermia with findings of hypo-spermatogenesis, Sertoli cell only syndrome and maturation arrest, testicular biopsy predicts the chances of sperm retrieval by microsurgical TESE for intracytoplasmic sperm injection (ICSI) and thus carries prognostic and therapeutic significance.

Keywords: Testicular biopsy, semen analysis, azoospermia, TESE, ICSI

1. Introduction

In the contemporary world scenario, Infertility is a major clinical problem with psychological, economic, legal and medical implications particularly in social fabric like India, with strong emphasis on child bearing. According to WHO, Infertility is a disease of reproductive system defined by failure to achieve the clinical pregnancy after 12 months or more of regular unprotected sexual intercourse in a women < 35 years or 6 months in women \geq 35 years^[1, 2]. Present statistics reveal that primary infertility ranges between 3.9% – 16.8 %^[3]. Male infertility is the cause in 23% of Indian couples seeking treatment^[4]. Male factor infertility is considered when sperm parameters are below the WHO normal values and represented by alteration in sperm concentration and /or motility and/or morphology in at least one sample of two sperm analyzes, collected 1 to 4 weeks apart^[5, 6].

A multidisciplinary approach involving Urologist, Gynecologist and pathologist is warranted in evaluation of male infertility.

Correspondence

Dr. Srinivas DD Gubbala
Associate Professor,
Department of Pathology,
Kamineni Institute of Medical
Sciences, Sreepuram,
Nalgonda, Narketpalli,
Telangana, India

Causes of male infertility are most easily divided into 3 major categories: pretesticular, testicular, and post-testicular. The pretesticular causes of infertility include extragonadal endocrine disorders, originating in the hypothalamus, pituitary, or adrenals, and have an adverse effect on spermatogenesis through aberrant hormonal stimulation or suppression. The testicular causes of infertility are primary defects of the testes. These may be congenital or occur secondarily to environmental insults or other disease processes. The post-testicular causes of infertility consist primarily of obstructions of the ducts leading away from the testes [7]. A bewildering array of diagnostic options are available for evaluation of infertile males and these include semen analysis, testicular biopsy and hormonal analysis. Hormonal analysis is done to assess the Hypothalamo-pituitary-Gonadal axis and is adequate for guiding the management of pre-testicular causes of infertility. But the testicular and post-testicular etiologies mandate a thorough sequential evaluation as documented in Figure 1. Semen analysis is the basic and the most important investigation and guides the further diagnostic workup [8, 9]. The Role of testicular biopsy in this process is being re-evaluated. Testicular biopsy plays a distinctive role in the diagnosis of obstructive azoospermia and in these men, surgical repair of the genital tract may be feasible and result in the presence of spermatozoa in the semen and spontaneous pregnancies [10]. For men with non-obstructive forms of severe oligo-spermia and azoospermia testicular biopsy has a predictive value for retrieval of spermatozoa for intracytoplasmic sperm injection (ICSI) [11]. In the era of ICSI, testicular biopsy is usually performed in men with non-obstructive azoospermia (NOA) for spermatozoa extraction, the testicular sperm extraction (TESE) procedure. In about 50%–60% of men with NOA and in 100% of men with OA, spermatozoa can be retrieved from the testes and used for ICSI [12].

2. Aims and objectives

1. To re-evaluate the role of testicular biopsy in male factor infertility and guide in planning the management protocols.

2. To identify potential candidates who would benefit from assisted reproductive techniques.

3. Material and methods

The present study was conducted at the Department of pathology, Kamineni Institute of Medical Sciences, Narketpally over a period of 3 years, starting from June 2015 to June 2018. This study was a prospective study and involved schematic evaluation of male infertility (Figure-1) which included clinical history, physical examination, semen analysis, hormone analysis, radiological evaluation (Scrotal and trans-rectal Ultrasonography) for obstructive etiology and finally testicular biopsy.

Prior informed consent was taken from all the patients and the study was approved by Institutional Review Board of Kamineni Institute of Medical Sciences, Narketpally. 147 patients who presented to OPD with primary male infertility were clinically evaluated and Semen analysis was the basic initial investigation done. Total sperm count was calculated, motility checked and morphology analyzed for any abnormal forms. Semen samples were collected after prerequisite three days of abstinence in the laboratory room and spermatozoa were counted using the Neubauer chamber under high power in all four WBC squares using semen diluting fluid. Cases were categorized into three groups i.e. group I with azoospermia, group II with oligospermia (count <15 million / ml) and group III with normal count. Azoospermia is defined as complete absence of spermatozoa in two evaluated semen specimens. WHO recommends that semen specimen must be centrifuged and the pellet checked for sperms before branding as Azoospermia. Semen specimen with counts less than 15 million/ml is classified as Oligospermia. To evaluate the motility, a small drop of liquefied semen was placed on a prewarmed slide, covered with a cover slip and was seen under high power. Sperm morphology was analyzed on Papanicolaou stained smears prepared from the pellet following centrifugation and abnormalities are documented. Trans-rectal and scrotal ultrasound was done in cases with abnormal semen parameters to identify varicocele and obstruction at the level of vas deferens and epididymis.

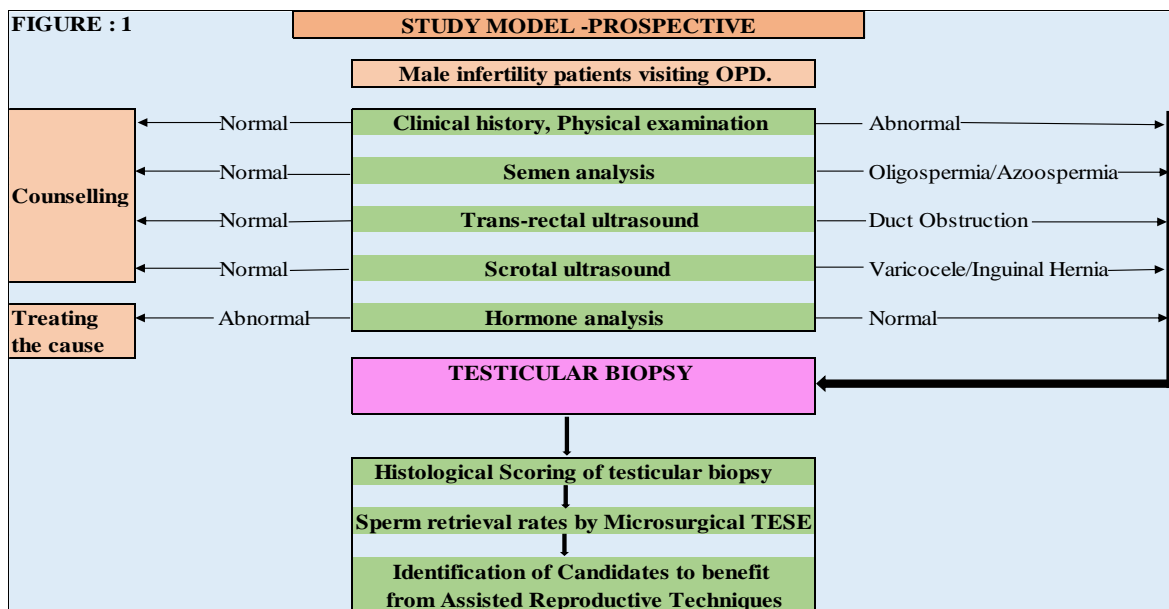


Fig 1: Study Model - Prospective
~ 153 ~

Based on clinical history, thorough clinical examination, radiological findings and abnormal findings (Azoospermia, Oligospermia) on semen analysis 71 cases were selected for testicular biopsy. The Peak age of incidence was from 25 to 35 years.

3.1 Inclusion criteriae for testicular biopsy

1. All cases presenting with oligospermia and Azoospermia.
2. Cases of azoospermia with clinically and radiologically documented obstruction (Obstructive azoospermia).
3. All cases of Non-obstructive Azoospermia.

3.2 Exclusion criteriae

1. All infertile males with normal semen parameters directed to counselling centers.
2. All infertile males with abnormal hormonal parameters who would benefit from hormone manipulation therapy.

3.3 Procedure

Testicular biopsy was performed as day-care surgery in an outpatient clinic by urologist under local anesthesia. An adequate piece of testicular tissue approximately 3 mm x 3 mm x 3 mm size was removed using “Window’s microsurgical technique”.

3.4 Tissue Handling

Specimen is placed in Bouin’s fixative and after fixation the tissue was processed and paraffin embedded. Sections were cut and stained with hematoxylin and eosin stain. For

adequate classification of spermatogenesis, the removed tissue should contain at least 75 seminiferous tubules.

3.5 Interpretation of Testicular Biopsy

Currently, there is no agreement on systemic reporting of testicular biopsies. Terms used are not standardized and the most commonly used histopathological classification of testicular biopsy depends on the presence and the amount of spermatogenesis, maturation of germinal cells and presence of associated tubular atrophy, interstitial fibrosis and Leydig cell hyperplasia. In view of wide variation in the reporting of testicular biopsy specimens we prepared a diagnostic algorithm (Figure 2) based on approved references for reporting of histological findings on testicular biopsy. (7) In the present study, testicular biopsy was reported individually by two different pathologists.

3.6 Scoring of Spermatogenesis

- Five histological patterns of spermatogenesis were defined:
- 1) Hyalinization of seminiferous tubules (Seminiferous tubule Hyalinization)
 - 2) No germ cells within the seminiferous tubules (Sertoli cell-only syndrome)
 - 3) Incomplete spermatogenesis, not beyond the spermatocyte stage with complete absence of spermatids and mature spermatozoa (Maturation arrest)
 - 4) All germ cell stages present including spermatozoa, but there is a distinct decline in the number of germ cells (Hypo spermatogenesis)
 - 5) Normal spermatogenesis.

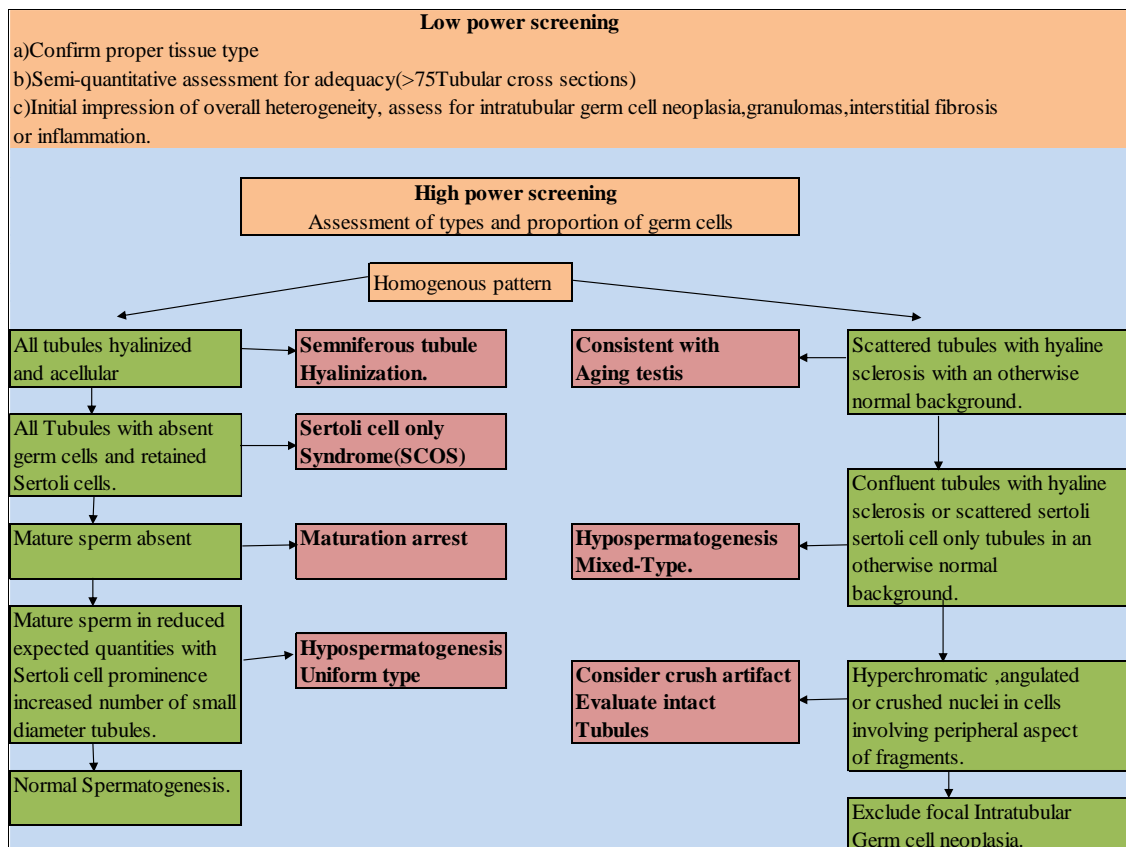
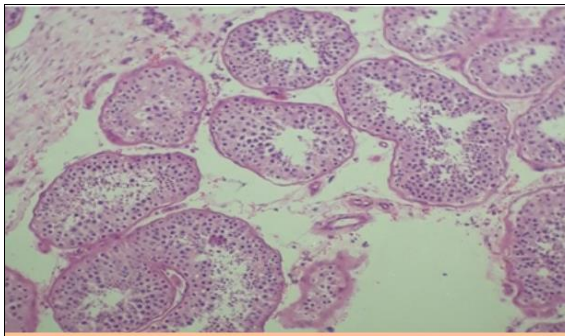


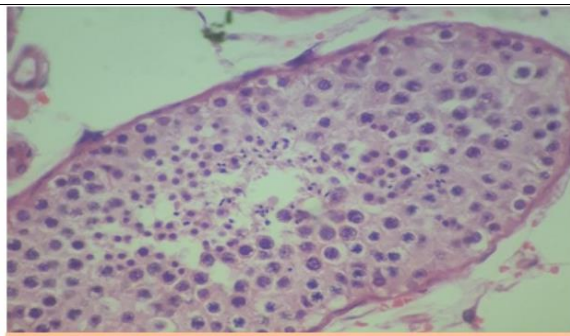
Fig 2: Diagnostic algorithm for testicular biopsy interpretation for male infertility

4. Observations/Results

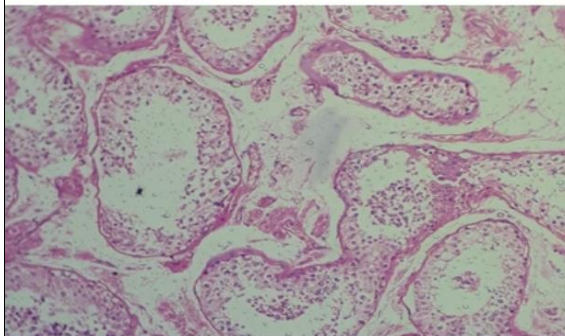
4.1 Microscopy: Histo-morphological findings of Testicular biopsy



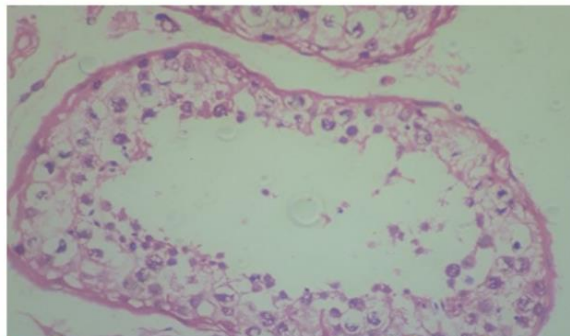
A: Normal Spermatogenesis H/E X 100



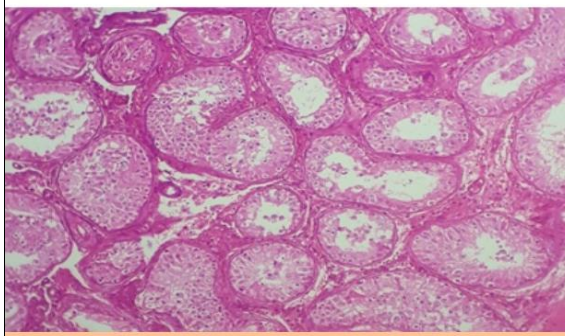
B: Normal Spermatogenesis H/E X 400



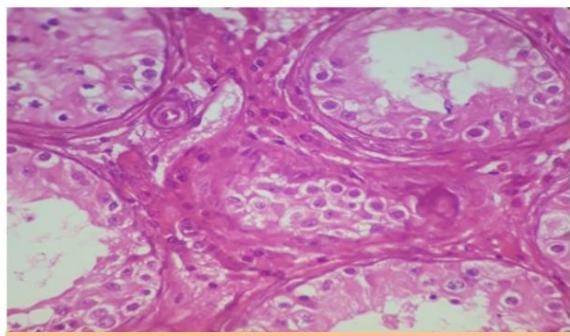
C: Hypo-spermatogenesis. H/E X 100



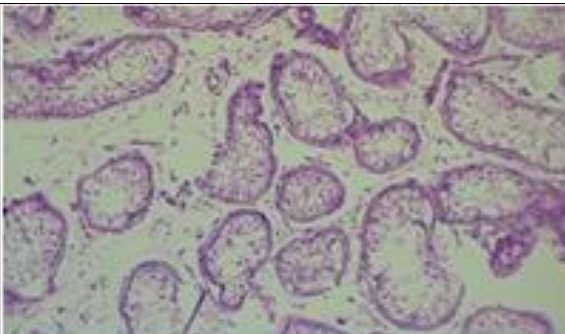
D: Hypo-spermatogenesis. H/E X 400



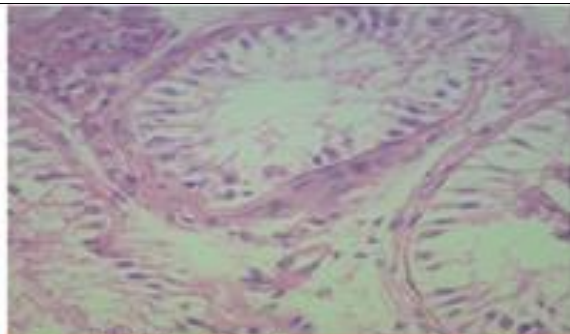
E: Maturation Arrest. H/E X100



F: Maturation Arrest. H/E X 400

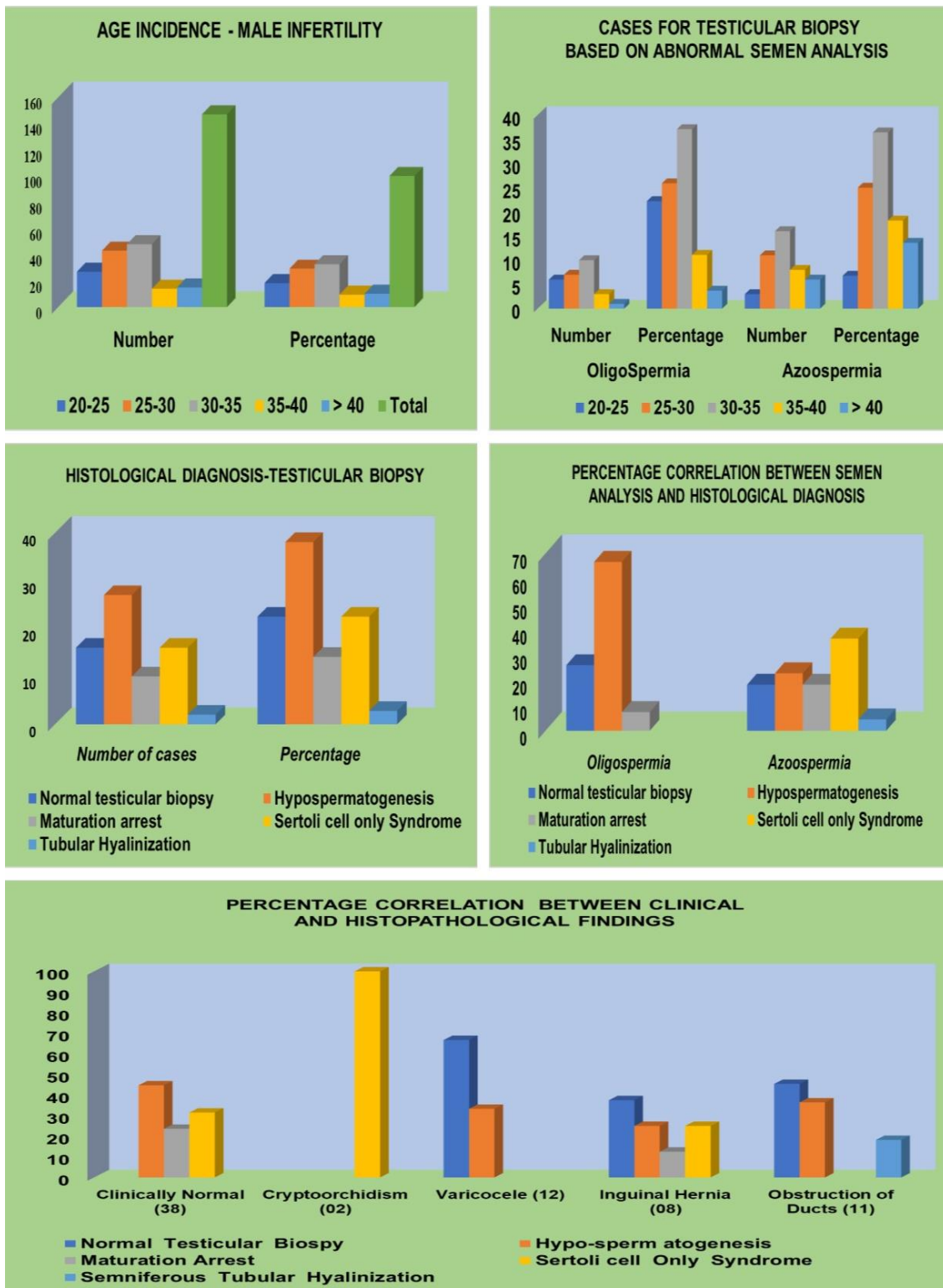


G: Sertoli cell Only Syndrome. H/E X100



G: Sertoli cell Only Syndrome. H/E X100

4.2 Graphical Representation of Results



4.3 Statistics

Table 1: Age wise Distribution of cases of Male Infertility who underwent semen analysis

AGE (in Yrs.)	Number	Percentage
20-25	27	18.3%
25-30	43	29.3%
30-35	48	32.7%
35-40	14	9.5%
> 40	15	10.2%
Total	147	100%

Table 2: Age-wise Distribution of cases for Testicular biopsy based on abnormal

Semen analysis				
Positive Cases	OligoSpermia		Azoospermia	
AGE (in Yrs.)	Number	Percentage	Number	Percentage
20-25	6	22.2%	3	6.8%
25-30	7	25.9%	11	25.0%
30-35	10	37.1%	16	36.4%
35-40	3	11.1%	8	18.2%
> 40	1	3.7%	6	13.6%
Total	27	100%	44	100%

Table 3: Histopathological diagnosis of testicular biopsy

Histopathological diagnosis	Number of cases	Percentage
Normal testicular biopsy	16	22.5%
Hypo-spermatogenesis	27	38.1%
Maturation arrest	10	14.1%
Sertoli cell only Syndrome	16	22.5%
Tubular Hyalinization	02	2.8%
Total	71	100%

Table 4: Correlation between semen analysis and Histological Diagnosis.

Histopathological diagnosis	Oligospermia	Azoospermia
Normal testicular biopsy	07 (25.9%)	08 (18.2%)
Hypo-spermatogenesis	18 (66.7%)	10 (22.7%)
Maturation arrest	02 (7.4%)	08 (18.2%)
Sertoli cell only Syndrome	0	16 (36.4%)
Tubular Hyalinization	0	02 (4.5%)
Total	27(100%)	44(100%)

Table 5: Correlation between Clinical diagnosis and Histological diagnosis.

Clinical Diagnosis	Histological Diagnosis				
	Normal Testicular Biopsy	Hypo-sperm atogenesis	Maturation Arrest	Sertoli cell Only Syndrome	Seminiferous Tubular Hyalinization
(Total Cases: 71)					
Clinically Normal (38)	0	17(44.7%)	09(23.6%)	12(31.5%)	0
Crypto-orchidism (02)	0	0	0	02(100%)	0
Varicocele (12)	08(66.7%)	04(33.3%)	0	0	0
Inguinal Hernia (08)	03(37.5%)	02(25.0%)	01(12.5%)	02(25.0%)	0
Obstruction of Ducts /Epididymis (11)	05(45.4%)	04(36.4%)	0	0	02(18.2%)

4.4 Interpretation of the Results

- Total 147 patients visited OPD for evaluation of male infertility and semen analyses was done as basic initial investigation. Oligospermia was reported in 27 patients and Azoospermia in 44 patients (Table-2). Majority of the patients with abnormal sperm parameters were in the age group 25-35, accounting for 64% of cases.
- Testicular biopsy was done in all 71 patients presenting with abnormal semen findings and histological findings are documented. Hypo-spermatogenesis was the most common histological finding accounting for 38.1% of cases, was associated with 66.7% of cases with oligospermia 22.7% of cases with Azoospermia and majority of cases were clinically normal (Refer to Table 3, 4, 5).
- Second most common histological abnormality reported was Sertoli cell only syndrome/Germ cell aplasia (22.5%). All cases of Sertoli cell only syndrome present with azoospermia and majority of patients were clinically normal with no documented obstructive etiology. There were however two cases of cryptorchidism with histological findings of Sertoli cell only syndrome.
- Most common histological finding in patients with azoospermia was Sertoli cell only syndrome accounting for (36.4%) of cases. Oligospermia was commonly associated with Hypo-spermatogenesis (66.7%).
- Majority of cases of Varicocele revealed Normal spermatogenesis (66.7%) on biopsy. Four cases of varicocele presented with hypo-spermatogenesis.
- In cases who presented Inguinal hernia, the most common finding on testicular biopsy was Normal spermatogenesis (37.5%). Two cases each presented with hypo-spermatogenesis, Sertoli cell only syndrome and one case presented with maturation arrest.
- Most frequent morphological feature associated with radiologically documented obstructive cases was Normal Spermatogenesis (45.4%). However, hypo-spermatogenesis was found in four cases and tubular hyalinization in two other cases with obstructive etiology.
- In clinically normal patients with no obvious obstructive etiology, hypo-spermatogenesis (44.7%) was the most common finding.
- On follow-up from the Department of Infertility medicine, sperms were retrieved from all cases of Hypo-spermatogenesis. Sperm retrieval rates were 70% and 31.3% in maturation arrest and Sertoli cell only syndrome respectively (Refer to Table-7).

5. Discussion

With rapid strides being made in various fields of medicine, the management of male factor infertility too needs to be rationalized with a multidisciplinary approach involving pathologist gynecologist and urologist. However, the key to success remains in unlocking / decoding the complexities of spermatogenesis to identify potential candidates who could benefit from assisted reproductive technology [13]. With the advent of micromanipulation techniques in the field of fertility management, the therapeutic role of testicular biopsy is being reevaluated as identification of even a single viable sperm can be used to fertilize the ovum [14]. Testicular biopsy provides valuable information to the urologist and/or andrologist by categorizing men with azoospermia for purposes of diagnosis, prognosis and treatment [15]. With an aim to identify potential candidates with male infertility who

would benefit from assisted reproductive techniques, we planned and executed our prospective study involving all patients with male factor infertility who visited the OPD. After ascertaining clinical history and physical examination, semen analysis was the basic investigation done and the patients with abnormal semen parameters were identified. Azoospermia was found in 44 patients (62%) and oligospermia in 27 patients (38%). Most common age group with semen abnormalities was 25-35, accounting for 64% of cases. Results were comparable with reference studies [16, 17]. Scrotal and transrectal ultrasound was done to identify the patients with obstructive etiology in cases with abnormal semen parameters. Testicular biopsy was done in all patients with male factor infertility, abnormal semen parameters, normal hormonal results and radiologically documented obstructive cases.

Table 6: Correlation of Histological Diagnosis between various Reference studies.

Histopathological diagnosis	Purohit <i>et al.</i>	Ahmad <i>et al.</i>	Parikh <i>et al.</i>	Present study
Normal testicular biopsy	16.0%	35.0%	36.3%	22.5%
Hypo-spermatogenesis	26.0%	10.0%	7.5%	38.1%
Maturation arrest	8.0%	7.5%	11.3%	14.1%
Sertoli cell only syndrome (SCOS)	26.0%	7.5%	18.8%	22.5%
Seminiferous tubules hyalinisation	18.0%	35.0%	11.3%	2.8%

Hypo-spermatogenesis was the most common histological finding accounting for 38.1% of cases in our study. Hypo-spermatogenesis was associated with 66.7% of cases with oligospermia, 22.7% of cases with azoospermia and majority of cases were clinically normal. The results were comparable to work done by Purohit *et al* as hypo-spermatogenesis was the most common finding in 26% of cases in that study [16]. In reference studies done by Ahmad *et al* and Parikh *et al.* the most common finding was normal spermatogenesis, and in their study hypo-spermatogenesis was reported in 10% and 7.5% cases respectively [17, 19].

Second most common histological abnormality reported was Sertoli cell only syndrome/Germ cell aplasia (22.5%). All cases of Sertoli cell only syndrome present with azoospermia and majority of patients were clinically normal with no documented obstructive etiology. There were also two cases of cryptorchidism with histological findings of Sertoli cell only syndrome. These findings correlated with reference studies. (Parikh *et al.* (18.75%), Purohit *et al.* (26%) [16, 17].

Most common histologic finding in cases with Azoospermia was Sertoli cells only syndrome (36.4%) followed by Hypo-spermatogenesis (22.7%). In studies done by Trupti *et al.* and Ahmad *et al.* normal spermatogenesis was the common presentation [16, 19]. Oligospermia was commonly associated with Hypo-spermatogenesis. These findings correlated with study done by Parikh *et al.* [17]

Most common histological finding in patients with varicocele and inguinal hernia was normal spermatogenesis. Four cases of varicocele and two cases of inguinal hernia presented with hypo-spermatogenesis. Azoospermia resulting from chronic venous congestion and consequent

increased scrotal temperature was alleviated after surgical correction and fertility was recovered. These findings correlated with study done by Parikh *et al.* [17]

In clinically normal patients with no obvious obstructive etiology, hypo-spermatogenesis (44.7%) was the most common finding followed by germ cell aplasia reported in 31.5% of cases. In patients presenting with oligospermia and hypo-spermatogenesis cigar smoking, wearing tight under garments and exposure to heat might be the probable causes and fertility can be achieved in these patients by avoidance of these factors [18, 20]. Whereas Azoospermia who presented with germ cell aplasia carried poor prognosis and can only benefit from assisted reproductive techniques.

Most frequent morphological feature associated with cases with obstruction of vas deferens was normal spermatogenesis. Four cases presented with Hypo-spermatogenesis and two cases presented with Maturation arrest and tubular hyalinization. These findings correlated with reference studies [17]. Surgical correction of the defects resulted in the improved ejaculate and fertility was recovered in all cases.

On follow-up of all these cases in the Department of Infertility medicine, sperm retrieval rates were best for cases with histological presentation of Hypo-spermatogenesis (100%) and was least for cases with Sertoli cell only syndrome (31.3%). Sperms were retrieved from 70% of cases who presented with maturation arrest. Findings of our study correlated with other reference studies. Table 7 summarizes the results of studies that have compared the histological results of the testicular biopsy to the sperm retrieval rate [21, 22, 23].

Table 7: Correlation between Sperm Retrieval Rate (SRR%) by TESE and Histological Diagnosis.

Study	Sperm Retrieval Rates (SRR%)		
	Hypo-spermatogenesis	Maturation Arrest	Sertoli Cell only syndrome
Okada <i>et al.</i>	100%	75%	34%
Ramaswamy <i>et al.</i>	81%	44%	41%
Tsujimura <i>et al.</i>	100%	75%	23%
Present study	100%	70%	31.3%

Thus, in our study patients with obstructive azoospermia and findings of normal spermatogenesis and hypo-spermatogenesis on testicular biopsy had very good prognosis as surgical repair of the defects recovered fertility in majority of cases and in the rest, sperms were retrieved by microsurgical TESE. However, patients with non-obstructive azoospermia and Sertoli cell only syndrome carry poor prognosis and testicular biopsy only predicts the chances of sperm retrieval for ICSI in these patients.

6. Conclusion

- The role of testicular biopsy is reevaluated in the management of Male factor infertility and carries diagnostic and prognostic significance.
- A diagnostic testicular biopsy performed in men with azoospermia, normal testicular volume and normal reproductive hormones differentiates between obstructive and non-obstructive azoospermia.
- In patients with obstructive azoospermia presence of normal spermatogenesis and hypo-spermatogenesis has very good prognosis as surgical repair of the defects recovers fertility in majority of cases.
- In patients with non-obstructive azoospermia with findings of hypo-spermatogenesis, Sertoli cell only syndrome and maturation arrest testicular biopsy predict the chances of sperm retrieval by microsurgical TESE for intracytoplasmic sperm injection (ICSI).
- Sperm retrieval is usually good in men with hypo-spermatogenesis and limited in men with Sertoli cell-only syndrome.

7. References

1. Zegers-Hochschild F, Adamson GD, de Mouzon J, Ishihara O, Mansour R *et al.* International Committee for Monitoring Assisted Reproductive Technology (ICMART) and the World Health Organization (WHO) revised glossary of ART terminology, *Fertil Steril.* 2009; 92:1520-4.
2. Practice Committee of the American Society for Reproductive Medicine. Definitions of infertility and recurrent pregnancy loss. *Fertil Steril.* 2008; 90(5):S60.
3. Calverton, Maryland, USA: ORC Macro and the World Health Organization; World Health Organization. Infecundity, Infertility, and Childlessness in Developing Countries. DHS Comparative Reports No 9, 2004.
4. Zargar AH, Wani AI, Masoodi SR, Laway BA, Salahuddin M. Epidemiologic and etiologic aspects of primary infertility in the Kashmir region of India. *Fertil Steril.* 1997; 68:637-43.
5. 4th ed. Cambridge: Cambridge University Press;. World Health Organization. WHO Laboratory Manual for the Examination of Human Semen and Semen-Cervical Mucus Interaction, 1999, 1-86.
6. Plachot M, Belaisch-Allart J, Mayenga JM, Chouraqui A, Tesquier L, Serkine AM. Outcome of conventional IVF and ICSI on sibling oocytes in mild male factor infertility. *Hum Reprod.* 2002; 17:362-9.
7. Lisa Cerilli A, Wayne Kuang, David Rogers. A Practical approach to testicular biopsy interpretation for Male infertility. *Arch Pathol Lab Med.* 2010; 134:1197-1204.
8. Sarkar S, Henry JB. Andrology laboratory and fertility assessment. Clinical diagnosis and management by clinical methods. 19th edition, 1996, 507-514.
9. World Health Organization. Laboratory Manual for the Examination of Human Semen; 2nd edition, 2015.
10. Dohle GR, Jungwirth A, Colpi G, Giwercman A, Diemer T. European Association of Urology Guidelines on Male Infertility. ed. Arnhem: EAU, 2010, 1-70.
11. Devroey P, Liu J, Nagy Z, Tournaye H, Silber SJ *et al.* Normal fertilization of human oocytes after testicular sperm extraction and intracytoplasmic sperm injection. *Fertil Steril.* 1994; 62:639-41.
12. Gert Dohle R, Saad Elzanaty, Niels Van Casteren J. Testicular biopsy: Clinical Practice and Interpretation. *Asian Journal of Andrology.* 2012; 14:88-93.
13. Dolores DM, Cheng Y, Sertoli-Sertoli, Sertoli Germ. Cell Interactions and Their Significance in Germ Cell Movement in the Seminiferous Epithelium during Spermatogenesis; *Endocrine Reviews.* 2004; 25(5):747-806.
14. Chapter in a book: Marc Goldstein; Testicular biopsy. In: Walsh; Retic; Vaughan Wein, eds. Campbell's Urology; 8th edition; W.B. Saunders and company, 2002, 1534-1537.
15. Male Infertility Best Practice Policy Committee of the American Urological Association; Practice Committee of the American Society for Reproductive Medicine. Report on optimal evaluation of the infertile male. *Fertil Steril.* 2006; 86(5):S202-S209.
16. Purohit TM, Purohit MB, Dabhi BJ. Study of semen analysis and testicular biopsy in infertile male. *Indian J. Pathol Microbiol.* 2004; 47(4):486-490.
17. Parikh UR, Goswami HM, Deliwala KJ, Shah AM, Barot HP. Testicular biopsy in Male infertility: Study of 80 Cases. *JIMSA.* 2012; 25(2):75-77.
18. Marshburn PB, Sloan CS, Hammond MG. Semen quality and association with coffee drinking, smoking, and ethanol consumption. *Fertil. Steril.* 1989; 52:162-165.
19. Ahmad M, Ahmad M, Ahmad R, Khan N. Role of testicular biopsy in male infertility. *Pak armed Forces Med J.* 2002; 52(1):66-71.
20. Trends of male factor infertility, an important cause of infertility: A review of literature *J Hum Reprod Sci.* 2015; 8(4):191-196.
21. Okada H, Dobashi M, Yamazaki T, Hara I, Fujisawa M *et al.* Conventional versus microdissection testicular sperm extraction for non-obstructive azoospermia. *J Urol.* 2002; 168:1063-7.

22. Ramasamy R, Schlegel PN. Micro-dissection testicular sperm extraction: effect of prior biopsy on success of sperm retrieval. *J Urol.* 2007; 177:1447-9.
23. Tsujimura A, Matsumiya K, Miyagawa Y, Tohda A, Miura H *et al.* Conventional multiple or microdissection testicular sperm extraction: a comparative study. *Hum Reprod.* 2002; 17:2924-9.