



ISSN (P): 2617-7226
ISSN (E): 2617-7234
www.patholjournal.com
2019; 2(2): 423-425
Received: 16-05-2019
Accepted: 18-06-2019

Dr. Harika P
IIIrd Year Postgraduate,
Department of Pathology,
Kamineni Academy of Medical
Sciences and Research Centre,
Hyderabad, Telangana, India

Dr. Shailaja Prabhala
Professor, Department of
Pathology, Kamineni
Academy of Medical Sciences
and Research Centre,
Hyderabad, Telangana, India

Dr. Srirambhatla Annapurna
Associate Professor,
Department of Radiodiagnosis,
Kamineni Academy of Medical
Sciences and Research Centre,
Hyderabad, Telangana, India

Dr. Ashok Kumar Deshpande
Professor and Head,
Department of Pathology,
Kamineni Academy of Medical
Sciences and Research Centre,
Hyderabad, Telangana, India

Corresponding Author:
Dr. Shailaja Prabhala
Professor, Department of
Pathology, Kamineni
Academy of Medical Sciences
and Research Centre,
Hyderabad, Telangana, India

Intussusception due to multiple submucosal lipomas in an adult: A rare case report

Dr. Harika P, Dr. Shailaja Prabhala, Dr. Srirambhatla Annapurna and Dr. Ashok Kumar Deshpande

DOI: <https://doi.org/10.33545/pathol.2019.v2.i2g.138>

Abstract

The occurrence of intussusception in adults is rare, accounting for less than 5% of all cases of intussusceptions and almost 1-5% of bowel obstruction. The condition is found in less than 1 in 1300 abdominal operations and 1 in 100 patients operated for intestinal obstruction. The child to adult ratio is more than 20:1. We report a rare case of ileocolic intussusception in an adult secondary to ileal lipomas. CECT revealed jejuno-ileo intussusceptions. Later laparotomy with reduction of jejunoileal intussusception with resection and anastomosis of small intestine was performed. Pathological examination confirmed multiple submucosal lipomas with mild ischemic changes in the intestine.

Keywords: Intussusception due, submucosal lipomas, adult, rare case report

Introduction

Intussusception of bowel is a condition in which proximal bowel segment (intussusceptum) invaginates into an adjacent distal segment (intussusciptiens) causing bowel obstruction.

Adult cases account for only 5% of all cases of intussusceptions [1]. The etiology and presentation of intussusceptions in adults are quite different from those in children. The clinical presentation in adults has nonspecific signs and symptoms, making it difficult to differentiate from other causes of abdominal pain.

Main causes of intussusception are inflammatory diseases, polyps, adhesions, benign or malignant tumors and motility disorders. Among the benign causes, lipoma is rare constituting only 10% of total benign tumors. Gastrointestinal lipomas are common in colon (65%) and in small intestine (20%-25%). Of these, 5% of submucosal lipomas are multiple. ¹ Lipomas of the small bowel are rare, benign mesenchymal tumors. They are mostly located in the colon, followed by small bowel, and occasionally foregut. Smaller lesions are asymptomatic, but a lesion >2 cm can cause acute symptoms, such as intussusception or hemorrhage [2].

Operative intervention is required in the presence of peritonitis, perforation, massive hemorrhage, intussusception or complete obstruction.

We report a case of complete small bowel obstruction with intussusception, secondary to multiple submucosal lipomas in the distal jejunum.

Case report

A 37 years old female presented with pain in abdomen and multiple episodes of bilious vomiting. She had associated fever, chills and generalized body pains since 4 days. No history of loose stools, constipation, malena, burning micturition, change in bowel habits or weight loss was noted. On general examination, patient was conscious and coherent. Per abdomen was soft, distended, with decreased bowel sounds. Guarding and rigidity were seen. Other systems were normal. Complete blood picture, coagulation profile, liver function tests were within normal limits.

Radiological investigation / USG abdomen revealed cholelithiasis, mild bilateral pleural effusion, minimal free fluid in peritoneal cavity. CT Scan revealed jejuno-ileal intussusception with acute small bowel obstruction, but lipomas could not be visualised.

Laparotomy with reduction of jejunoileal intussusception with resection and anastomosis of small intestine was performed.

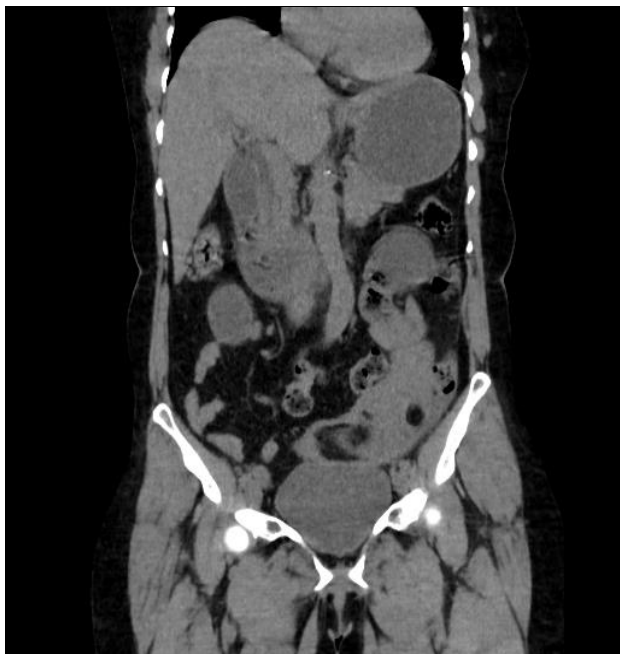

Fig 1: CT Scan revealed jejuno-ileal intussusception with acute small bowel obstruction.

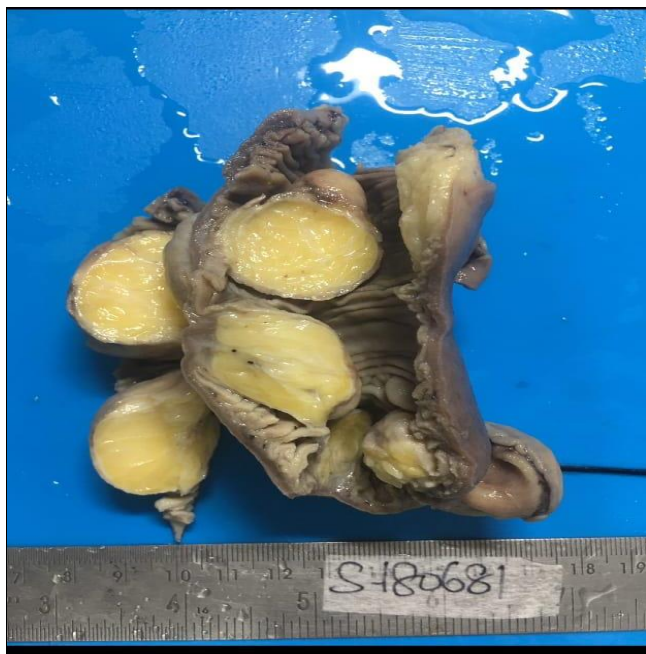

Fig 2: Segment of small intestine with submucosal lipomas

Gross examination: (Figure 2) Received a part of intestine measuring 12 cm in length. Attached mesentery measured 8x2 cm. External surface of intestine showed patchy exudates. On cut surface showed three polypoidal masses with surface ulceration, largest measuring 3.5x2.5x2.5 cm and smallest measuring 2x2 cm. Cut surface of the masses were greasy and yellowish in color. The intervening mucosa was edematous and flattened.

Microscopy: (Figure 3) Multiple sections revealed ulcerated colonic mucosa and mild lymphocytic infiltration in lamina propria. The submucosa showed well encapsulated lesions with mature adipocytes arranged in lobules with intervening thin fibrovascular septa, suggestive of submucosal lipomas.

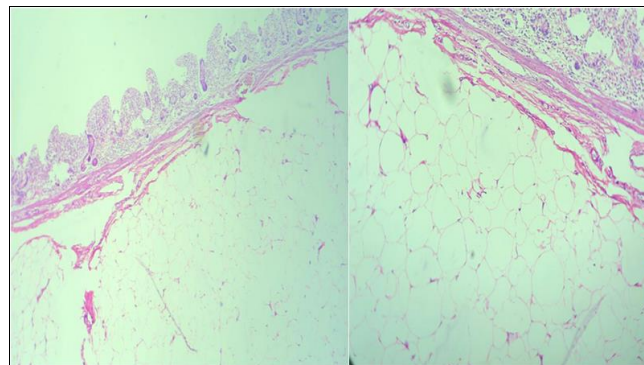


Fig 3: Microscopy showed submucosal lipomas (Hematoxylin and eosin staining, 40X and 100X)

Discussion

Adult intussusception is a rare condition. Intussusceptions are classified into four categories according to location: a. enteric—confined to the small bowel, b. colonic— involvement of large bowel exclusively, c. ileocolic— prolapse of the ileum into the colon through the ileocaecal valve and d. ileocaecal—where the ileocaecal valve acts as the lead point [3].

Childhood intussusception is idiopathic in the majority of cases. In adult intussusception, 90% of cases have identifiable aetiology which acts as the lead point [4]. The majority of intussusceptions occurring in the small bowel are mostly secondary to benign lesions, among which colocolonic cases are more likely to have a malignant aetiology such as adenocarcinoma or lymphoma neoplasms.

Benign lesions account for 30% of cases; which include adenomatous polyps, lipomas, haemangiomas, neurofibromas and leiomyomas [5].

Lipomas are the second most common benign tumors found in the colon, incidence ranging between 0.035 to 4.4%. [6] The majority arise from the submucosa, but occasionally they originate from the subserosa. They are mostly isolated. However, only 10% of cases are multiple, particularly caecum and right hemi-colon may have multiple lipomas. [6] Small intestinal lipomas account for 20-25% of GI tract lipomas and multiple small intestine lipomas are extremely rare [7].

The size of lipomas reported in the literature varies from 2 mm to 30 cm. Small lipomas are mostly asymptomatic and are usually detected incidentally. Larger lipomas are more frequently symptomatic, those greater than 4 cm are considered giant lipomas [8].

They can mimic symptoms of colonic malignancy and present in similar age groups. They may cause bleeding, obstruction or intussusceptions. The main symptom reported is chronic, colicky abdominal pain. Adult intussusception usually has a non-specific presentation and is often not considered in the differential diagnosis for abdominal complaints. The classical pediatric triad of abdominal pain, bloody diarrhea and a tender abdominal mass is absent in adults. Abdominal pain, nausea, altered bowel habit and bleeding per rectum may be reported in adults, or the patient may present with features of acute bowel obstruction [9].

Preoperative diagnosis of lipomas can be accomplished by imaging or endoscopic modalities. Computed tomography (CT) scans of the abdomen may reveal a mass with a uniform and fatty tissue density consistent with a lipoma. Small intestinal imaging demonstrating radiolucency and a

'squeeze sign' indicating an altered configuration during peristalsis are characteristic findings in lipomas^[10]. More advanced methods like capsule endoscopy and digital balloon endoscopy, are useful for the diagnosis of lipomas within the small intestine. Colonoscopy can detect lipomas within the colon. The 'cushion sign', the 'tenting effect' and the 'naked fat sign' are characteristic findings of lipomas in the colon^[10, 11].

Endoscopic removal of larger lipomas (>2 cm) is associated with a greater risk of perforation^[12]. Therefore, large symptomatic lipomas usually require surgical resection.

Operative intervention is often required for complete small bowel obstructions. Partial obstructions can be managed conservatively with nil per oral, fluid resuscitation, and nasogastric tube decompression; however, if there are no signs of improvement operative intervention may be indicated. Exploratory laparotomy and diagnostic laparoscopy are surgical options that are determined by patient characteristics and surgeon preference. This case represents a rare occurrence of a complete small bowel obstruction secondary to multiple submucosal lipomas.

Conclusion

Lipomas are benign mesenchymal tumours of adipose tissue, though common at other sites, they are rare in GIT. Larger lesions can cause acute symptoms, such as intussusception or hemorrhage. The etiology of intussusception in adults can be difficult and malignant lesions need to be ruled out that necessitate extensive surgical procedures.

References

1. Shehzad KN, Monib S, Ahmad OF, Riaz AA. Submucosal lipoma acting as a leading point for colocolic intussusception in an adult; Journal of Surgical Case Reports Rep, 2013, 10.
2. Bravo AM, Mansilla CV, Fraguas FN, Vicent FJG. Ileocolic intussusception due to giant ileal lipoma: review of literature and report of a case. Int J Surg Case Rep. 2012; 3:382-4.
3. Dean DL, Ellis FH, Sauer WG. Intussusception in adults. AMA Arch Surg. 1956; 73(1):6-11.
4. Weilbaecher D, Bolin JA, Hearn D, Ogden W. Intussusception in adults. Review of 160 cases. Am J Surg. 1971; 121:531-35.
5. Begos DG, Sandor A, Modlin IM. The diagnosis and management of adult intussusception. Am J Surg. 1997; 173:88-94.
6. Castro EB, Stearns MW. Lipoma of the large intestine: a review of 45 cases. Dis Colon Rectum. 1972; 15:441-44.
7. Konik RD, Rhodes RA. Complete small bowel obstruction without intussusception due to a submucosal lipoma, Journal of Surgical Case Reports. 2018; 7:1-3.
8. Bahadursingh AM, Robbins PL, Longo WE. Giant submucosal sigmoid colon lipoma. AM J Surg 2003; 186:81-2.
9. Marinis A, Yiallourou A, Samanides L, Dafnios N, Anastopoulos G, Vassiliou I *et al*. Intussusception of the bowel in adults: a review. World J Gastroenterol 2009; 15:407-11.
10. Cakmak GK, Emre AU, Tascilar O, Bektas S, Ucan

BD, Irkorucu O *et al*. Lipoma within inverted Meckel's diverticulum as a cause of recurrent partial intestinal obstruction and hemorrhage: a case report and review of literature. World J Gastroenterol. 2007; 13:1141-1143.

11. Jiang RD, Zhi XT, Zhang B, Chen ZQ Li. Submucosal lipoma: a rare cause of recurrent intestinal obstruction and intestinal intussusception. J Gastrointest Surg 2015; 19:1733-5.
12. Pfeil SA, Weaver MG, Abdul-Karim FW, Yang P. Colonic lipomas: outcome of endoscopic removal. Gastrointest Endosc. 1990; 36:435-8.