



ISSN (P): 2617-7226
ISSN (E): 2617-7234
www.patholjournal.com
2021; 4(1): 165-169
Received: 20-01-2021
Accepted: 24-02-2021

Dr. Ankita Varma
Junior Resident, Department
of Pathology, Subharti Medical
College, Meerut, Uttar
Pradesh, India

Dr. Vinay Bharat
Professor, Department of
Pathology, Subharti Medical
College, Meerut, Uttar
Pradesh, India

Dr. Shweta Chawla Grover
Professor, Department of
Pathology, Subharti Medical
College, Meerut, Uttar
Pradesh, India

Dr. Rani Bansal
Professor and Head,
Department of Pathology,
Subharti Medical College,
Meerut, Uttar Pradesh, India

Corresponding Author:
Dr. Ankita Varma
Junior Resident, Department
of Pathology, Subharti Medical
College, Meerut, Uttar
Pradesh, India

Cytologic comparative analysis between stained and unstained smears of urine sediment in urinary tract pathologies

Dr. Ankita Varma, Dr. Vinay Bharat, Dr. Shweta Chawla Grover and Dr. Rani Bansal

DOI: <https://doi.org/10.33545/pathol.2021.v4.i1c.343>

Abstract

Aim: To analyse the routine microscopic examination of urine specimens in urinary tract pathologies and compare the cytological examination of unstained and stained urine sediment samples (Papanicolaou and Romanowsky stains) to establish clinicocytological correlation.

Material and Method: The present study was conducted among 500 patients coming to either OPD /admitted to CSSH with urinary pathology. In patients with a clinical history suggestive of any urinary pathology freshly voided urine samples were collected. Samples were centrifuged at 1500rpm for 10 minutes. In case of less cellularity, Cytospin at 3000rpm for 5-10 minutes was done. From the sediment, three smears were prepared i.e. smear 1 (routine urine microscopy), smear 2 by Romanowsky stain (Leishman Geimsa) and smear 3 by Papanicolaou method.

Results: In the current study, urinary tract pathologies were found to be more common in females (326) as compared to males (174). Majority of patients were in the 3rd and 4th decade of life accounting for 184 cases (38%) and 153 cases (36%) respectively. Stained smears detect high n/c ratio, pus cells, bacilli/fungi and bare nuclei among 95.85%, 99.07%, 99.07% and 0% of UTI samples respectively, while unstained smears detect high n/c ratio, pus cells, bacilli/fungi and bare nuclei in 91.24%, 96.3%, 97.23% and 44.24% of the UTI samples respectively.

Conclusion: We can conclude that this study demonstrates the high correlation between the cytological examination of urine specimen in fresh smears and in the Papanicolaou-stained smears.

Keywords: Urine, pathology, tumour, cytology

Introduction

Urine is a body fluid that has the potential to answer many of the body's secrets ^[1]. Evaluation of microscopic urinary findings rests on adequate recognition of cellular elements and casts. This has always been a difficult task since the cells may originate from diverse tissues such as epithelial layers of the urinary and genital tracts, blood and connective tissue sources, or tumors, and are likely to show variable degrees of degeneration, viability, permeability, and density when shed into the urine ^[2].

Cytological examination of urine includes urine sediment analysis that may be freshly urinated, catheterized or obtained by percutaneous puncture ^[3]. Urine cytology is useful in the detection and diagnosis of various benign diseases and conditions such as infections of different etiologies and in distinguishing hematuria from the upper and/or lower urinary tract. Indications for cytological examination of the urine are: screening of asymptomatic patients exposed to carcinogens, triage of symptomatic patients, detection of non-neoplastic, premalignant and malignant lesions, metastatic tumors, lesions that cannot be detected by cystoscopy or biopsy, and monitoring of therapy (Ostović, 2015) ^[4]. The cytological diagnosis of these neoplastic cells is very difficult in low-grade tumors. The sensitivity of cytology for the diagnosis of bladder cancer is not very high; this is mainly due to the minimal morphological differences between the normal cells and the cellular groups exfoliated from low-degree tumors ^[5, 6]. The aim of this study is to explore the importance of role of cytological examination of urinary samples observed in fresh stained (by Papanicolaou's and Leishman Geimsa) and unstained smears of urine sediment in urinary tract pathologies. The observation of fresh urine sediment can identify different pathologies that will subsequently be correlated by Pap staining.

Material and Method

The present study was conducted in the Department of Pathology at Subharti Medical College and associated Chhatarpati Shivaji Hospital. It is a hospital based prospective cross sectional study (October 2018-June 2020) was conducted 500 patients coming to either OPD /admitted to CSSH with urinary pathology. Patients were enrolled in the study after obtaining written informed consent and approval from Institutional Ethical Committee. Patients were recruited according to the following inclusion and exclusion criteria:

Inclusion criteria

1. Patients with a clinical history suggestive of any urinary pathology.
2. Freshly voided urine samples (< 1hour)

Exclusion criteria

1. Sample from patients of renal transplant rejection.
2. Stored urinary samples (>1 hour)

In patients with a clinical history suggestive of any urinary pathology freshly voided urine samples were collected.

Method of sample collection

Subjects were instructed to collect an early mid stream clean catch urine in a sterile container. The males were instructed to first clean genitals with soap and water and then collect urine after retracting prepuce and the glans penis. The women were asked to collect urine after careful anogenital toilet with soap and water. The female patients were instructed to separate the labia with fingers, while collecting the urine. Samples were centrifuged at 1500rpm for 5-10 minutes. In case of less cellularity, Cytospin at 3000rpm for 5-10 minutes was done.

From the sediment, three smears were prepared as mentioned below:

Smear 1: Routine urine microscopy

The fresh urine sediments smears were examined through microscope.

Procedure: Urine was mixed thoroughly by centrifugation. About 10 ml of urine was poured off aseptically in a sterile labeled 15 ml conical centrifuge tube and was centrifuged for 10 minutes at 1500 rpm. Supernatant was poured off carefully into another tube. Sediment was remixed by tapping the bottom of the tube and then one drop of well

mixed sediment was placed on a clean dry glass slide and was covered with a cover slip.

The urine was then examined under microscope with 10 X objective to obtain an overall picture of the deposit and 40 X objective was used to examine urine for pus cells, epithelial cells, RBC, casts, crystals etc. and was reported as follows:

- a. In urine sediment under 40 X objective pus cells were reported as the number of pus cells/HPF. Pus cell 0-5/HPF was taken as test negative and Pus cell >5/HPF was taken as test positive.
- b. Epithelial cells were reported as number of epithelial cells/HPF
- c. RBC were reported as number of RBC/HPF
- d. Crystal were reported as few, moderate or many/HPF
- e. Casts were reported as number of cast/LPF.

Smear 2: Romanowsky stain (Leishman Geimsa)

The staining would be carried out on urinary sediments completely dried and fixed with methanol for two minutes.

Smear 3: PAP

The accumulated sediments was spread on a microscope slide, where they were left to concentrate, but they were not allowed to reach total dryness. Then the slides have to be carefully submerged in 96% ethanol to fix the sediments for a minimum of 30 minutes. Finally, they will be stained using the Papanicolaou method.

Statistical analysis: Data so collected was tabulated in an excel sheet, under the guidance of statistician was analysed using SPSS 22.00 for windows (SPSS inc, Chicago, USA).

Results

In the current study, urinary tract pathologies were found to be more common in females (326) as compared to males (174). Majority of patients were in the 3rd and 4th decade of life accounting for 184 cases (38%) and 153 cases (36%) respectively. Non-tumoral pathologies were found to be more prevalent as compared to tumoral comprising about 479 (95.8%) patients while the tumoral pathologies were found in 21patients (4.2%). Majority of overall tumor cases were present in 31 to 50 years of age group. Majority of cases of non tumoral pathology (67%) were present in 31 to 50 years of age group. High grade urothelial tumors were found maximum in 31-40 year age group (4) while low grade urothelial tumors in 41-50 year age group (6) as shown in table 1.

Table 1: Distribution among different age groups according to Non tumoral and tumoral pathologies

Non tumoral Pathology	Number	Age Group (in years)					
		4-10	11-20	21-30	31-40	41-50	51-60
A) UTI	217	38	42	40	47	49	1
B) Lithiasis	138	10	4	13	51	60	0
C) Nephritic syndrome	64	1	0	4	41	18	0
D) Nephrotic syndrome	37	0	0	2	25	10	0
E) Acute Kidney Injury	23	1	0	2	13	7	0
Total	479	50	46	61	177	144	1
Percentage (out of 479 cases)		10.43	9.60	12.73	36.95	30.06	0.2
Tumoral Pathology							
A) Urothelial carcinoma	18	1	1	1	7	8	0
1. Low Grade carcinoma	12	1	1	1	3	6	0
2. High Grade carcinoma	6	0	0	0	4	2	0
B) Non-Urothelial carcinoma	3	0	0	0	0	1	2
1. Adenocarcinomas	1	0	0	0	0	0	1

2. Squamous carcinomas	2	0	0	0	0	1	1
Total	21	1	1	1	7	9	2
Percentage (out of 21)		4.76	4.76	4.76	33.33	42.85	9.52

As per table 2; stained smears detect high n/c ratio, pus cells, bacilli/fungi and bare nuclei among 95.85%, 99.07%, 99.07% and 0% of UTI samples respectively, while unstained smears detect high n/c ratio, pus cells, bacilli/fungi and bare nuclei in 91.24%, 96.3%, 97.23% and 44.24% of the UTI samples respectively. Stained smears detect flat umbrella cells, abundant quantity of leucocytes and red blood cells and crystals in 92.75%, 82.61%, 87.68% and 94.20% respectively in urinary samples of kidney lithiasis, while unstained smears detect flat umbrella cells,

abundant quantity of leucocytes and red blood cells and crystals in 86.23%, 93.47% and 81.15% respectively in urinary samples of kidney lithiasis. Unstained smears detect lipid droplets, oval fat bodies, hyaline & wax cast and cholesterol crystals in 91.89%, 89.18%, 89.18% and 94.59% respectively, while stained smears detect droplets, oval fat bodies, hyaline & wax cast and cholesterol crystals in 94.59%, 0.81%, 92.29% and 92.29% respectively in urine samples of nephrotic syndrome.

Table 2: Examination of urinary samples of UTI, Kidney lithiasis, nephritic, nephrotic syndrome observed by fresh urine sediments and stained smears

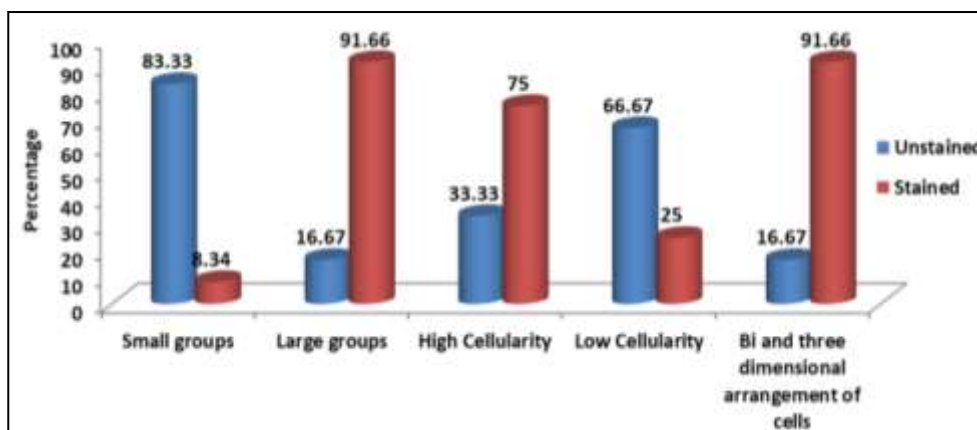
UTI (N=217)	Nucleomegaly of urothelial cells		Pus Cells		Bacilli/Fungi		Bare Nuclei	
	N	%	N	%	N	%	N	%
Unstained	198	91.24	209	96.3	211	97.23	96	44.24
Stained	208	95.85	215	99.07	215	99.07	103	47.46
Lithiasis (N=138)	Flat Group of Umbrella Cells		Abundant quantity of leukocytes and red cells		Crystals			
	N	%	N	%	N	%	N	%
Unstained	119	86.23	129	93.47	112	81.15		
Stained	128	92.75	114	82.61	121	87.68		
Nephritic Syndrome (N=64)	Isomorphic RBCs, RBC casts		Dysmorphic RBCs (acanthocytes)		WBCs, WBC casts			
	N	%	N	%	N	%	N	%
Unstained	61	95.31	0	0	33	51.56		
Stained	5	0.78	59	92.18	44	68.75		
Nephrotic Syndrome (N=37)	Lipid droplets		Oval fat bodies		Hyaline and waxy casts		Cholesterol Crystals	
	N	%	N	%	N	%	N	%
Unstained	34	91.89	33	89.18	33	89.18	35	94.59
Stained	35	94.59	3	0.81	36	92.29	36	92.29

Graph 1 showed that unstained smears detect small groups, large groups, high cellularity, low cellularity and bi & three arrangement of cells in 83.33%, 16.67%, 33.33%, 66.67% and 16.67% respectively, while stained smears detected groups of small groups, large groups, high cellularity, low cellularity and bi & three arrangement of cells in 8.34%, 91.66%, 75%, 25% and 91.66% respectively in urine samples of low grade urothelial tumors.

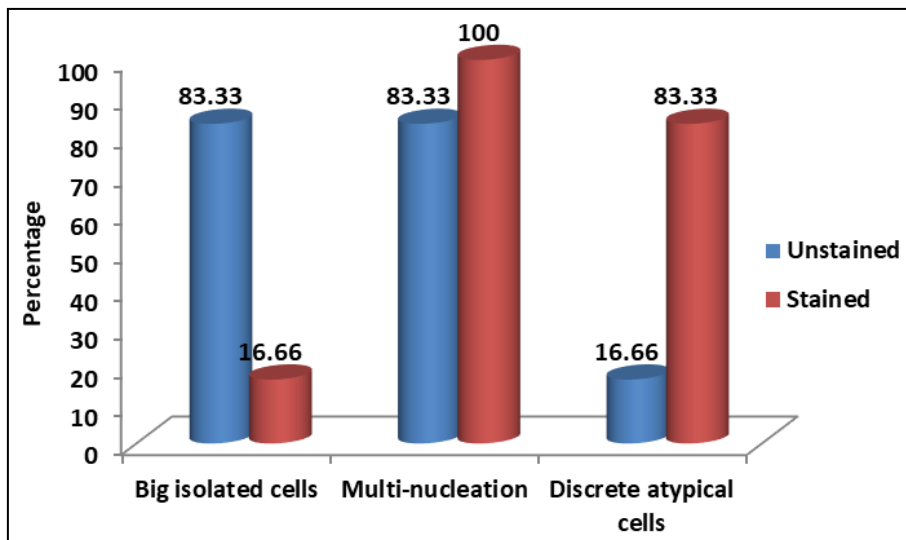
Graph 2 showed that unstained smears detect big isolated cells, multinucleation and discrete atypical cells in 83.33%,

83.33% and 16.66% respectively, while stained smears detect big isolated cells, multinucleation and discrete atypical cells in 16.6%, 100% and 100% respectively in urine samples of high grade urothelial tumors.

It was observed that unstained smears detect anisokaryosis, marked vacuolization, neoplastic cells and signet ring cells in the one case studies. Stained smears detected anisokaryosis, marked vacuolization, neoplastic cells and signet ring cells in the urine sample of adenocarcinomas (table 3).



Graph 1: Examination of urinary samples of low-grade urothelial tumors by fresh urine sediments and Papanicolaou & H/E smears



Graph 2: Examination of urinary samples of high-grade urothelial carcinomas by fresh urine sediments and Papanicolaou & H/E smears

Table 3: Examination of urinary samples of Squamous carcinomas (Non-urothelial tumors) observed by fresh urine sediments and Papanicolaou& H/E smears

Squamous carcinomas (N=2)	Refringence of cells		Predominance of fibrillar shapes/grouped in a squamous pearl		Keratinizing neoplastic cells		Bizarre shapes (spindle-like cells, tadpole cells, squamous pearls)	
	N	%	N	%	N	%	N	%
Unstained	1	50	1	50	1	0	0	0
Stained	0	0	0	0	2	100	2	100

(Percentage is calculated out of total number of cases of Squamous cell carcinoma; N=02)

Discussion

Examination of crystals in the urinary sediment (crystals of uric acid, urate, phosphate, oxalate) is of special value. Description of urinary sediment is one of the most demanded laboratory tests, and the literature provides important information about urinary sediment⁷. Scientific studies in our country are insufficiently addressed by this topic. Therefore this study was conducted to assess the correlation that exists between cytological examination of urinary samples observed in fresh stained (by Papanicolaou's and Leishman Geimsa) and unstained smears of urine sediment in urinary tract pathologies. The observation of fresh urine sediment can identify different pathologies that will subsequently be corroborated by Pap staining.

In our study, urinary tract pathologies were found to be more common in females (326) as compared to males (174). Male: female ratio was 1.7:1 Gabriel Alin Iosob et al.^[82] in their study too revealed similar female predominance i.e. pathological evidence came from 36 males and 64 women.

In the present study, majority of cases of non tumoral pathology (67%) were present in 31 to 50 years of age group. High grade urothelial tumors were found maximum in 31-40 year age group (4) while low grade urothelial tumors in 41-50 year age group in our study. Alin Iosob et al⁸ in their study reported that among patients with urinary pathology, the most affected age group is 61-70 years, while the least affected age groups are 31-40 and 81-90 years.

Stained smears detect nucleomegaly, pus cells, bacilli/fungi and bare nuclei among 95.85%, 99.07%, 99.07% and 0% of UTI samples respectively, while unstained smears detect nucleomegaly, pus cells, bacilli/fungi and bare nuclei in 91.24%, 96.3%, 97.23% and 44.24% of the UTI samples respectively in our study. Khatun K et al.^[91] in their study too reported that pus cells 0-5/HPF were found in 19 (31.67%) cases and >5/HPF were found in 41(68.33%)

which is in accordance with our study.

Palaoro Luis Alberto et al.^[5] in their study reported that in fresh smears, they observed flat groups of small urothelial cells, umbrella cells, and an abundant quantity of leukocytes and red cells, while in stained smears, they saw a predominance of small cells and some umbrella cells (of the ureters, bladder or urethra), some of which presented reactive changes: hyperchromatic nuclei with homogeneous chromatin, which may present with regular chromocenters. Similar findings were observed in our study. Cytologic analysis of the urinary sediment can point to some diseases associated with erythrocytosis such as lithiasis, glomerulonephritis, or it can help diagnose bladder inflammation (Ostović, 2015)^[4].

In cases of low grade urothelial carcinoma, unstained smears detect small groups, large groups, high cellularity, low cellularity and bi & three dimensional arrangement of cells in 83.33%, 16.67%, 33.33%, 66.67% and 16.67% respectively, while stained smears detected small and large groups, high and low cellularity and bi & three dimensional arrangement of cells in 8.34%, 91.66%, 75%, 25% and 91.66% respectively in urine samples of low grade urothelial tumors. Palaoro Luis Alberto et al.^[10] in their study reported approximately similar findings i.e. fresh smear showed groups of small cells, some of them with a three-dimensional effect while stained smear showed abundant cells, exfoliated, in compact groups, with uniform nuclei, showing bi- and three-dimensional effect (papillary arrangement).

Only 1 case of adenocarcinoma was found in our study. It was observed that unstained smears detect anisokaryosis, marked vacuolization and signet ring cells in the one case. Stained smears detected anisokaryosis, marked vacuolization, and signet ring cells in the urine sample of adenocarcinoma. In a study by Palaoro Luis Alberto et al.

[10], the least frequent among urinary bladder cancers was adenocarcinoma (2% of the malignant tumors). The fresh smears show cellular groups that suggest the presence of this pathology owing to the presence of very vacuolated cells, arranged in three-dimensional form, in a compact group. The Papanicolaou stain confirmed the diagnosis of adenocarcinoma, showing the typical three dimensional vacuolated cellular groups, with irregular chromatin and macronucleoli. These findings were similar to our study.

In our study, 2 cases of squamous cell carcinoma were found. Unstained smears detect anisokaryosis refringence of cells, predominance of fibrillar shapes/ grouped in a squamous pearl in one of the two cases studied. Both the cases showed keratinizing neoplastic pearls and bizarre shapes in 50% and 50% respectively, while stained smears detect keratinizing neoplastic pearls and bizarre shapes in 100% and 100% respectively in urine samples of squamous cell carcinomas in the present study. According to Palaoro Luis Alberto et al. [10], squamous carcinomas of the bladder are not frequent, although there are endemic zones in the world for this disease, related to the presence of the parasite *Schistosoma haematobium* in the contaminated waters (for example, in the proximities of the river Nile). Such keratinized tumors show refringent neoplastic cells in the fresh smears. This carcinoma develops the well-known bizarre forms: Spindle like cells, tadpole cells, and squamous pearls. The images of the fresh smears show a strong correlation with the stained samples.

We hope this new vision of the urinary sediment examination will allow an improvement in patient care as because it would avoid many expensive investigations and delay of treatment.

Conclusion

We can conclude that this study demonstrates the high correlation between the cytological examination of urine specimen in fresh smears and in the Papanicolaou-stained smears. For this reason, the identification of cells of the urinary tract in samples observed in fresh sediments is important as a primary diagnostic procedure between non-tumoral and tumoral pathologies, with a later diagnostic confirmation with the Papanicolaou method. The methodological proposal presented in this study aims to establish an early cytodiagnosis, which may help diminish the morbidity and mortality associated with this type of pathology of the urinary tract.

References

1. Sikirica M, Bobetić-Vranić T, Flegar-Meštrić Z, Kardum-Skelin I, Juretić D. Standardized analysis of supravivally stained urine sediment. *Biochemia Medica* 2002;12(3-4):57-72.
2. Kern WH. Epithelial cells in urine sediments. *Am J Clin Pathol* 1971;56:67-72.
3. Chew DJ, Di Bartola SP. Interpretation of Canine and Feline Urinalysis. Clinical Handbook Series. USA: The Gloyd Group, Inc. Wilmington, Delaware 2004.
4. Ostović KT. Cytologic urinalysis with hematuria and glomerulonephritis. *Paediatr Croat* 2015;59(Sup11):66-71.
5. Poulakis V, Witzsch U, De Vries R, et al. A comparison of urinary nuclear matrix protein-22 and bladder tumour antigen tests with voided urinary cytology in detecting and following bladder cancer: The prognostic value of false-positive results. *BJU Int.* 2001;88:692-701.
6. Placer J, Espinet B, Salido M, Sole F, Gelabert-Mas A. Correlation between histologic findings and cytogenetic abnormalities in bladder carcinoma: A FISH study. *Urology* 2005;65:913-8.
7. Schaeffer AJ. Infections of the urinary tract. In: Walsh PC, Retik AR, Vaughan ED, Wein AJ, editors. *Campbell's Urology*, 8th edition. Philadelphia: WB Saunders Company 1998, 639-41.
8. Iosob GA, Prisecaru M, Stoica I, Comănescu L. Observations on normal and pathological cytology of the urinary sediment. *Studii și Cercetări* 2017;26:75-83.
9. Khatun K, Kamal AM, Rahman KA, et al. A comparative study of routine microscopic examination of urine in microbiology laboratories at primary and secondary level before and after implementation of standard operating procedure (SOP). *Journal of Dhaka Medical College* 2016;25(2):87-93.
10. Palaoro LA, Angerosa M. Correlation between the cytology of urine sediment in fresh sample and smears stained by Papanicolaou and Giemsa methods. *J Cytol* 2014;31(1):25-31.