



ISSN (P): 2617-7226
ISSN (E): 2617-7234
www.patholjournal.com
2021; 4(1): 174-175
Received: 28-12-2020
Accepted: 30-01-2021

Kute KV

Resident, Department of Pathology, Swami Ramanand Teerth Rural Government Medical College, Ambajogai, Beed, Maharashtra, India

Swami SY

Associate Professor, Department of Pathology, Swami Ramanand Teerth Rural Government Medical College, Ambajogai, Beed, Maharashtra, India

Narwade SB

Assistant Professor, Department of Pathology, Swami Ramanand Teerth Rural Government Medical College, Ambajogai, Beed, Maharashtra, India

Badlani KS

Assistant Professor, Department of Pathology, Swami Ramanand Teerth Rural Government Medical College, Ambajogai, Beed, Maharashtra, India

Corresponding Author:

Kute KV

Resident, Department of Pathology, Swami Ramanand Teerth Rural Government Medical College, Ambajogai, Beed, Maharashtra, India

Deciduos in a caesarean scar: A case report

Kute KV, Swami SY, Narwade SB and Badlani KS

DOI: <https://doi.org/10.33545/pathol.2021.v4.i1c.345>

Abstract

Cutaneous deciduos is an exceedingly rare manifestation of endometriosis potentially mistaken for malignancy and thus far documented solely within surgical scars. In the scars, the prevalence of surgically proven endometriosis is around 1.6% and is often difficult to diagnose due to its rarity. It is often confused with stitch granuloma, hernia, lipoma, cysts, desmoids tumor, sarcoma etc. Areas of myxoid change or marked decidual change in the stroma can make the recognition difficult. Here we present a case of caesarian scar deciduos in a 37-year-old female.

Keywords: caesarian scar, deciduos, endometriosis

Introduction

Endometriosis is the term used to describe the presence of endometrial tissue at sites other than the uterus. It may rarely arise from scar tissue due to previous abdominal surgery such as caesarean section or episiotomy and may present with some histological features of decidual change, fibrosis, hyperplasia, metaplasia and calcifications [1]. In the scars, the prevalence of surgically proven endometriosis is around 1.6% and is often difficult to diagnose due to its rarity [2].

Endometriosis is most commonly found in the pelvis including ovaries, uterine ligaments, rectovaginal septum, and peritoneum. Unusual sites of endometriosis have also been reported such as intestine, appendix, bladder and skin from scars, umbilicus, perineum and inguinal region. In most of the cases, it consists of both the endometrial glands and stroma but may also consist only of endometrial stroma [1].

Decidual cells outside the endometrium are named “deciduos” or “ectopic decidua”. This benign entity is the result of the metaplasia of sub-coelomic pluripotent mesenchymal cells to progesterone [2].

Case report

A 37-years old female, second gravida with a history of previous caesarean section 6 years ago underwent another caesarean section. LSCS [Lower segment caesarean section] was uneventful and a single live male baby was delivered. Intraoperatively the previous caesarean scar tissue showed focal nodular thickening. Scar tissue was excised and referred to histopathological examination. Specimen received in 10% formalin fixative measured 3x2x2 cm, externally firm in consistency and was attached with adipose tissue. Cut surface showed pinkish white areas along with adipose tissue. Representative sections microscopically revealed [Fig.1 & Fig.2] scar tissue composed of fibroblasts and collagen admixed with hypertrophic decidualized stromal tissue surrounding slit like endometrial glands. Individual stromal cells were polygonal with large nuclei and abundant eosinophilic cytoplasm at places showing hydropic changes.

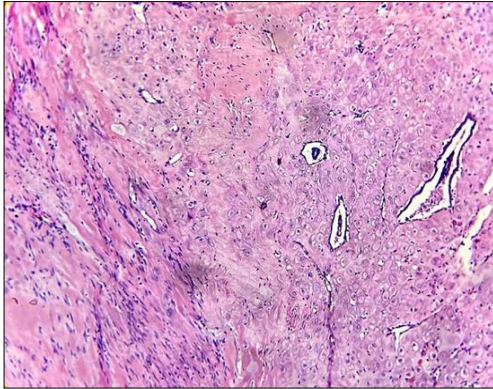


Fig 1: Scar decidualosis: shows hypertrophy of decidualized stromal tissue surrounding slit like endometrial glands. Scar tissue composed of fibroblasts is seen at the periphery. [H&E: 10X]

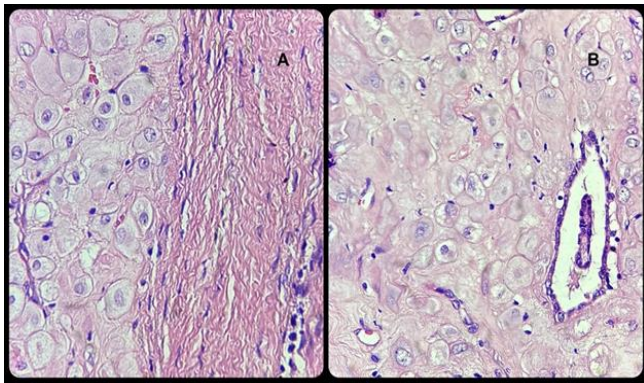


Fig 2[A, B]: Scar decidualosis: shows large polygonal decidual cells with homogenous eosinophilic cytoplasm and vacuolar degeneration surrounding the endometrial glands. [H&E: 40X]

Discussion

Decidualization is a pregnancy induced change in which there is conversion of the normal endometrium into a specialized uterine lining adequate for optimal accommodation of the gestation. In this condition there is hypertrophy of endometrial stromal cells and this leads to thickening of the normal endometrium and giving rise to the decidua. In rare cases there can be presence of ectopic decidua's during pregnancy due to hormonal effects on the ectopic endometrium and this phenomenon is called as decidualosis [1].

Endometriosis that responds to hormonal stimulation (deciduosis) is extremely rare in a surgical scar and is present in 0.1% women who have undergone caesarean section. Whenever endometriosis is present at a cutaneous site, there is nearly always associated with surgical scar [1]. Cutaneous decidualosis is an exceedingly rare manifestation of endometriosis potentially mistaken for malignancy and thus far documented solely within surgical scars [3].

Ectopic decidua was first described in 1864 by Walker von Solothurn during the observation of two ectopic pregnancies. The pathogenesis of ectopic decidua is not completely understood, but it is believed that it develops as a result of the metaplasia of subserosal stromal cells affected by progesterone during pregnancy. Deciduosis is a clinicopathological process distinct from endometriosis [4].

Decidualization is the hypertrophy of endometrial stromal cells by the effect of progesterone. Similarly, in pregnancy, ectopic stromal endometrial cells in endometriosis can also be transformed by the same mechanism and ectopic decidua (deciduosis) may occur [5]. In the absence of pregnancy,

ectopic decidual changes have been attributed to the stimulation of appropriate cells by progesterone and progesterone like substances from the corpus luteum or the adrenal cortex [6].

Deciduosis occurring in the caesarean scar may be secondary to iatrogenic transplantation of endometrium or extra-uterine decidual tissue into the incision during the caesarean section. The symptoms of scar endometriosis are related to the cutaneous mass or nodule that appears weeks to years after the surgery and in one study the average postoperative interval was 30 months.

Chatterjee reported that 71% cases of scar decidualosis followed abdominal hysterectomy over a study period of 5 years and the incidence of scar endometriosis in the patients who underwent hysterotomy during this period was 1.08%. Koger *et al.* reported 24 patients with surgical scar decidualosis in which majority of cases had cesarean section scar [1].

Decidual cells are generally large polygonal, with homogenous, eosinophilic cytoplasm and vacuolar degeneration at various rates can be seen in these cells as seen in the present case [7]. These cells are vimentin and progesterone-receptor-positive and focally positive for desmin and smooth muscle actin [8].

The treatment of decidualosis may be surgical or hormonal depending upon the circumstances, but usually surgical excision is sufficient for the treatment of non-decidualized and decidualized endometriosis of the abdominal wall or scar after Cesarean section [1].

Conclusion

Although the histologic diagnosis of endometriosis is usually easy, diagnostic problems can occur as a result of secondary changes such as decidual change as seen in the present case. It can be confused with neoplasm clinically and histologically. Histopathologist should be aware of this phenomenon to avoid erroneous diagnosis.

References

1. Saeed Alam, Huma Mushtaq, Salma Kafeel. Deciduosis in a cesarean scar. JIMDC 2013;2:32-34.
2. Lingegowda JB, Muddegowda PH, Koteswary P, Thamilselvi R. Scar endometriosis with decidual change. National Journal of Basic Medical Sciences 2016;7:52-54.
3. Kevaghn PF, James WP, Richard JM, Rebecca JR. Cutaneous decidualosis. J Am Acad Dermatol 2000;43:102-7.
4. Baroni Cruz D, Dhameer T, da Rocha VW *et al.* BMJ Case Rep 2014. doi:10.1136/bcr-2013-202480:1-2.
5. Barbieri M, Somigliana E, Oneda S, Ossola MW, Acaia B, Fedele L. Decidualized ovarian endometriosis in pregnancy: a challenging diagnostic entity. Hum Reprod 2009;24:1818-1824.
6. Kinra P, Sen A, Sharma JC. Ectopic decidual Reaction: A case report. MJAFI 2006;62:280-281.
7. Bolat F, Canpolat T, Tarim E. Pregnancy related peritoneal ectopic decidua [deciduosis]: Morphological and clinical evaluation. Turk J Pathol 2012;28:56-60.
8. Shukla S, Pujani M, Singh SK. Ectopic decidual reaction mimicking peritoneal tubercles: A report of 3 cases. Indian J Pathol Microbiol 2008;51:519-20.