



ISSN (P): 2617-7226
ISSN (E): 2617-7234
www.patholjournal.com
2021; 4(1): 143-147
Received: 04-11-2020
Accepted: 06-12-2020

Dr. Farah LR Al-Rufae
Al-Yarmook Teaching
Hospital Baghdad, Iraq

Dr. Saba FN Al-Ani
Al-Yarmook Teaching
Hospital, Baghdad, Iraq

Dr. Iman F Sirdar
Al-Yarmook Teaching
Hospital, Baghdad, Iraq

Dr. Khulood W Al-Jareh
Al-Yarmook Teaching
Hospital, Baghdad, Iraq

Corresponding Author:
Dr. Farah LR Al-Rufae
Al-Yarmook Teaching
Hospital Baghdad, Iraq

The usefulness of fine needle aspiration cytology in the diagnosis of parotid gland tumors

Dr. Farah LR Al-Rufae, Dr. Saba FN Al-Ani, Dr. Iman F Sirdar and Dr. Khulood W Al-Jareh

DOI: <https://doi.org/10.33545/pathol.2021.v4.i1c.337>

Abstract

Background: Various parotid gland diseases are seen clinically including inflammation, sialolithiasis, benign and malignant tumors. It is important to differentiate between these to make a correct diagnosis, the aim of this study is to assess the usefulness of fine needle aspiration cytology as a preoperative diagnostic tool in the diagnosis of parotid gland tumors.

Method: A retrospective study was done on 110 Iraqi patients with apparent parotid gland swelling, all patients were subjected to FNAC by using 22-gauge needle attached to a 10ml syringe with at least two needle passes were made for each patient.

Results: The number of cases in each category were: nondiagnostic 5.5% and in 94.5% were diagnostic. Neoplastic lesions were observed in 71.20% of patients, non-neoplastic lesions in 28.80% of patient.

Conclusion: Fine needle aspiration cytology is a reliable examination providing important information to the surgeon in the preoperative diagnostic assessment when Milan system was applied.

Keywords: the usefulness, fine needle aspiration cytology, diagnosis, parotid gland tumors

Introduction

Major salivary gland tumors account for 3% of head and neck cancers ^[1]. Malignant salivary gland neoplasm account more than 0.5% of all malignancies and approximately 3-5% of all head and neck cancer ^[2]. Benign tumors are more common than malignant tumors, the majority (85%) originated from parotid gland. the most common benign tumor is pleomorphic adenoma while mucoepidermoid carcinoma is the most common malignant tumor, Other causes of parotid gland masses include metastatic cancer, inflammatory conditions and lymphoma ^[3, 4]. Fine needle aspiration cytology (FNAC) is widely accepted modality of diagnosis in the preoperative assessment of the head and neck tumors ^[5]. Although FNAC was first described in 1930s, salivary gland FNAC is a relatively new discipline, having gained wide acceptance only in the past 40 years ^[6]. The procedure is a cytodagnostic method where by a needle is used to acquire a sample of cells and microparticles of tissue for morphological analysis ^[1]. Meta- analysis of published series indicate 96% sensitivity and 98% specificity for neoplasia whereas distinction between benign and malignant neoplasm has 79% sensitivity and 96% specificity. Because accuracy varies greatly among published studies, the utility of salivary gland FNA is highly practitioner-dependent ^[6]. However, the value of FNAC for the diagnosis of parotid gland masses, has been questioned due to its low sensitivity regarding malignancy, variation in reported results, and the belief that most parotid masses require surgery in any case ^[7, 8]. The precise classification of salivary gland neoplasm by FNAC is possible for many of the commonly encountered lesions but remain problematic for a number of less common entities ^[6].

FNAC is minimally invasive procedure that does not require anaesthesia ^[5]. It is well tolerated, simple, safe and cost-effect ^[7, 9]. Moreover, it can be easily repeated in the event of non-diagnostic results, thus improving diagnostic precision ^[10]. It is preferred biopsy method that poses minimal risk to the patient and provide excellent distinction between benign and malignant parotid tumors ^[1] The Milan System for Reporting Salivary Gland Cytopathology (MSRSGC) has been recently developed to standardize the terminology for reporting FNAC of salivary gland and to improve the communication between clinicians and pathologists. The MSRSGC is a seven-tiered classification system comprising: I, nondiagnostic;

II, nonneoplastic; III, atypia of undetermined significance (AUS); IVA, benign neoplasm; IVB, salivary gland neoplasm of uncertain malignant potential (SUMP); V, suspicious for malignancy (SM); and VI, malignant. It also provides estimated risk of malignancy (ROM) and clinical management recommendations for each category [11].

Patients and Methods

A retrospective study included a total of 110 patients who visited the Main Laboratory Division in Al- Yarmook Teaching Hospital in Baghdad during the period (January 2011-February 2019) complaining of apparent parotid gland swelling. The age of the patients ranged between (1-77 years). All patients were subjected to FNAC by using 22-gauge needle attached to a 10ml syringe with at least two needle passes were made for each patient. The aspirated material was expelled onto two slides then thin smears were done and fixed in alcohol immediately. Papanicolaou stain was used for slides staining. We classified our FNAC results into seven categories according the Milan System for Reporting Salivary Gland Cytopathology (MSRSGC) [11].

Statistical analysis was performed by using SPSS version 23 and different variables were analyzed.

Result

FNAC samples were obtained in 110 cases. The mean ± SD age was 44±18.5 years, ranging between 1-77 years, 59(53.6%) were female and 51(46.4%) were male, table -1-.

Table 1: Demographic character of studied patients

Variables	Number	Percentage
Age	<18 years	13 11.8%
	18-40 years	29 26.4%
	>40 years	68 61.8%
Gender	Female	59 53.6%
	male	51 46.4%

FNAC results were "non-diagnostic" in 6 patients (5.5%) and in 104 patients (94.5%) were diagnostic. Neoplastic lesions were observed in 74 (71.2%) patients and non-neoplastic lesions in 30(28.8%) patients, figure -1-.

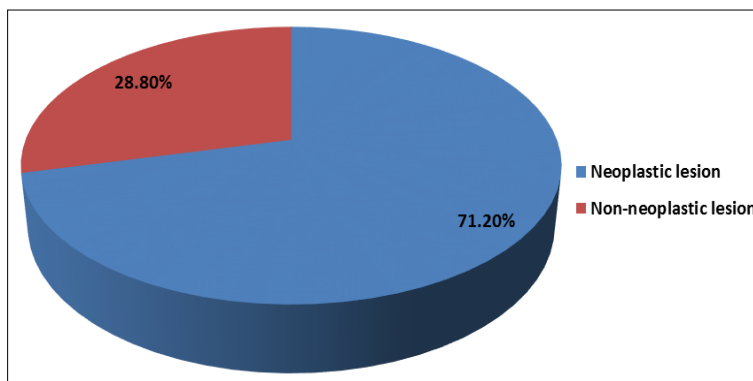


Fig 1: FNAC result of studied patients

The cytopathological features in a non-neoplastic lesion was shown in table -2-.

Table 2: Cytopathological diagnosis of non-neoplastic lesions among studied patients

Cytopathological diagnosis of non-neoplastic lesions	Number	Percentage
Lymphoepithelial sialadenitis	18	17.3%
Abscess	9	8.7%
Reactive lymphadenitis	1	0.96%
Chronic granulomatous inflammatory process	1	0.96%
Cyst	1	0.96%

Table 3: The cytopathological features in a neoplastic lesion shown in table-3

Cytopathological diagnosis of neoplastic lesions	Number	Percentage
benign epithelial cells	44	42.3%
pleomorphic adenoma	21	20.1%
Aus	6	5.7%
Suspicious	2	1.9%
Warthin	1	0.96%

Discussion

FNAC of salivary gland is used worldwide for the diagnosis and management of salivary gland tumors. It provides a minimally invasive, safe, cost-effective, and accurate technique that is extremely useful in identifying a

substantial subset of salivary gland nodules as benign and thus reduces unnecessary invasive surgical procedure in patients with benign diseases. In addition, it guides the further management strategy [12, 13]. The Milan System for Reporting Salivary Gland Cytopathology (MSRSGC) was introduced in 2018 [11]. The goal of the MSRSGC was to develop a practical, evidence-based, user-friendly, and internationally accepted classification system. The system includes characterization and management algorithms for each category. Salivary gland tumors are one of the most heterogeneous groups of neoplasms with cytopathological features overlapping among the entities, Due to those facts, salivary gland cytopathology is one of the most challenging areas of cytology [14]. In this study, FNAC samples were obtained in 110 cases ranging between (1-77) years, males formed 51(46.4%), while the females formed 59 (53.6%), this finding is in agreement with Esther *et al.* study [15].

Neoplastic Lesions: the study revealed that benign tumors were 46.9% from all neoplastic, this finding is in agreement with N. Fakhry *et al.*, and Deepti Arora *et al.* [3, 16]. the pleomorphic adenoma in current study represented 21.1% of neoplastic tumors, this finding is in agreement with Zerpa Zerpa V *et al.*, study [1] and also concordance with study of Lyu HX *et al.*, study [17] who reported the incidence of pleomorphic adenoma as 67.7%, Although most of these neoplasms were readily identified because of their biphasic pattern, comprising epithelial/myoepithelial cells and

magenta chondromyxoid predominantly epithelial types to predominantly stromal types which often poses diagnostic challenge to cytopathologists. If epithelial component predominates in smears, then the tumor needs to be differentiated from monomorphic adenoma, myoepithelioma and low-grade carcinoma. However, in cases of increased stroma with or without hyaline globules, it has to be differentiated from adenoid cystic carcinoma [18, 19]. If myxoid material is abundant and epithelial cells are sparse, then it can be mistaken for retention cyst cases, the myoepithelial cells have tremendous potential for differentiating into various cytomorphologic forms, a finding which is more evident on cytologic smears and are seen as plasmacytoid, spindle and stellate cells. The smears with predominance of plasmacytoid myoepithelial cells need to be differentiated from malignant lymphoma and plasma cell proliferation [20]. Warthin's tumor represent 0.96% of neoplasm, affecting only males and involving parotid gland. The similar results were obtained by Li *et al.*, study [21] and de Oliveira *et al.*, study [22]. The three main components that characterize the cytological smears of Warthin's tumor are oncocytes, lymphocytes and dirty fluid background, the differential diagnosis of Warthin's tumor includes lymphoepithelial cysts of salivary gland, chronic inflammatory and obstructive duct lesions exhibiting oncocytic metaplasia and lymphocytes [23, 24] and 1.9% case suspicious of malignancy, this in agreement with Rossi ED *et al.*, study [25]. In the suspicious for malignancy (SM) and malignant diagnostic categories, definitions and criteria are analogous to the same categories in other anatomic sites. Lesions classified as SM have features suggestive of malignancy but the sample is either deficient in the quality of the cellular features or the quantity of abnormal cells present. For salivary gland FNAC diagnosed as malignant, criteria are provided to enable cytologists to sub classify the tumors into low-grade and high-grade entities, since these designations have significant implications for patient management. Management of high-grade carcinomas may include radical surgical resection, sacrifice of major nerves, and neck dissection. The six-tier Milan system for reporting salivary gland cytopathology has been recently introduced with the support of the American Society of Cytopathology and the International Academy of Cytology with hopes of standardizing the reporting of salivary gland FNA [26]. The diagnostic category of AUS in the MSRSGC is defined as a salivary gland FNAC that lacks either qualitative or quantitative cytomorphologic features to be diagnosed with confidence as either nonneoplastic or neoplastic. It encompasses a heterogeneous group of lesions ranging from nonneoplastic to malignant. The histologic follow up of AUS cases showed nonneoplastic, malignant, benign neoplasm, and atypical [27]. In this study AUS 6(5.7%) by FNA only which may show ROM consider with Wang *et al.*, study [28] who reported a high ROM (61%) for "atypical" salivary gland FNA based on a multi-institutional study with 154 cases having histologic follow-up. Lymphoma also accounted for the most common malignant diagnosis or lower similar to the reports by others [29, 30].

Non-neoplastic lesions

In the current work, non-neoplastic lesions constituted 18.8% of adequate parotid salivary gland aspirates, this in agreement with Bhutani N *et al.*, study [31]. Lymphoepithelial sialadenitis was seen in 18(17.3%) followed by 1(0.96%) obtained in lymphoepithelial cyst, Non-neoplastic

Lymphocytic Cysts Salivary gland lesions that fall into this category are lymphoepithelial cysts. The term lymphoepithelial cyst (LEC) was introduced Ihrler S *et al.* [32] HIV-associated LEC usually manifest as multiple, bilateral lesions affecting the parotid glands. They may sometimes be the first manifestation of HIV infection. LEC can also occur in association with chronic infection and autoimmune sialadenitis, most commonly Sjögren syndrome [33]. In Sjögren syndrome, minor salivary glands tend to be involved. LEC are acquired cysts, postulated to either arise from cystic transformation of inclusions within intra-/peri-salivary gland lymph nodes or secondary to obstruction from lymphoid hyperplasia within the salivary gland [34]. Abscess 9 (8.7%) and this is agree with Yogambal *et al.*, study [35]. Reactive lymph node in our study included 1(0.96%) and this result disagrees with Howard *et al.*, study [27] who reported that reactive lymph node was the most common nonneoplastic diagnosis, Chronic granulomatous inflammatory Granulomatous infections of the salivary gland Affect the adjacent lymphatic system and the parotid gland. In fulminant cases, it affects the glandular parenchyma. Signs of the ailment can be moderate or gradual swelling of the ganglia may be present. It can be mistaken for a neoplastic tumor. The diseases that can lead to granulomatous infections are represented by TB, syphilis, actinomycosis, cat-scratch disease, toxoplasmosis and tularemia FNA may be negative in most of the cases. Granulomatous infection of the salivary glands can affect children but also old people and often lead to a gradual increase in the size of the salivary gland and lymph nodes and it can be mistaken for a neoplastic tumor [22]. Differential diagnosis is based on a carefully done anamnesis, on the physical examination and identifying the etiologic agent that can cause the disease [36].

References

1. Zerpa Zerpa V, Cuesta González MT, Agostini Porras G, Marcano Acuña M, Estellés Ferriol E, Dalmau Galofre J. Precisión diagnóstica de la citología por punción aspiración con aguja fina en tumores de la glándula parótida [Diagnostic accuracy of fine needle aspiration cytology in parotid tumours]. *Acta Otorrinolaringol Esp* 2014;65(3):157-61.
2. Tian Z, Li L, Wang L, Hu Y, Li J. Salivary gland neoplasms in oral and maxillofacial regions: A 23-year retrospective study of 6982 cases in an eastern Chinese population. *Int J Oral Maxillofac Surg* 2010;39(3):235-42.
3. Fakhry N, Santini L, Lagier A, Dessi P, Giovanni A. Fine needle aspiration cytology and frozen section in the diagnosis of malignant parotid tumours. *International Journal of Oral and Maxillofacial Surgery* 2014;43(7):802-5.
4. Andreasen S, Melchior LC, Kiss K, Bishop JA, Høgdall E, Grauslund M *et al.* The PRKD1 E710D hotspot mutation is highly specific in separating polymorphous adenocarcinoma of the palate from adenoid cystic carcinoma and pleomorphic adenoma on FNA. *Cancer Cytopathol* 2018;126(4):275-281.
5. David O, Blaney S, Hearp M. Parotid gland fine-needle aspiration cytology: An approach to differential diagnosis. *Diagnostic Cytopathology* 2007;35(1):47-56.
6. Chen L. *Cytology: diagnostic principles and clinical correlates*. LWW 2010.
7. Alphs HH, Eisele DW, Westra WH. The role of fine

- needle aspiration in the evaluation of parotid masses. Current opinion in otolaryngology & head and neck surgery 2006;14(2):62-6.
8. Singh A, Haritwal A, Murali B. Correlation between cytology and histopathology of the salivary gland. The Australasian medical journal 2011;4(2):66.
 9. O'donnell M, Salem A, Badger S, Sharif M, Kamalapurkar D, Liew T *et al.* Fine needle aspiration at a Regional Head and Neck Clinic: A clinically beneficial and cost-effective service. Cytopathology 2009;20(2):81-6.
 10. Jurczyk M, Peevey JF, Vande Haar MA, Lin X. Pitfalls of fine-needle aspiration cytology of parotid membranous basal cell adenoma-A review of pitfalls in FNA cytology of salivary gland neoplasms with basaloid cell features. Diagn Cytopathol 2015;43(5):432-7.
 11. Rossi ED, Baloch ZW, Puztaszeri M, Faquin WC. The Milan System for Reporting Salivary Gland Cytopathology (MSRSGC): an ASC-IAC-sponsored system for reporting salivary gland fine-needle aspiration. Acta Cytologica 2018;62(3):157-65.
 12. Jain R, Gupta R, Kudesia M, Singh S. Fine needle aspiration cytology in diagnosis of salivary gland lesions: A study with histologic comparison Cytojournal 2013, 10.
 13. Colella G, Cannavale R, Flamminio F, Foschini MP. Fine-needle aspiration cytology of salivary gland lesions: A systematic review. Journal of Oral and Maxillofacial Surgery 2010;68(9):2146-53.
 14. Tommola E, Tommola S, Porre S, Kholová I. Salivary gland FNA diagnostics in a real-life setting: one-year-experiences of the implementation of the Milan system in a tertiary care center. Cancers 2019;11(10):1589.
 15. Pantanowitz L, Thompson LD, Rossi ED. Diagnostic approach to fine needle aspirations of cystic lesions of the salivary gland. Head and neck pathology 2018;12(4):548-61.
 16. Dr. Deepti Arora, Dr. Rashmi Chauhan, Dr. Ankita Mittal, Dr. Faiyaz Ahmad, Dr. Seema Awasthi, Dr. Shyamoli Dutta. Practical implication of risk based categorization of salivary gland lesions on FNAC by Milan system: A two year retrospective study. International Journal of Clinical and Diagnostic Pathology 2019;2(2):443-449.
 17. Lyu HX, Wang ZR, Gao YQ, Yu M, Li BQ, Zhang ZB. [Clinical pathologic analysis on 3 724 cases of salivary gland tumors]. Zhonghua Kou Qiang Yi Xue Za Zhi. 2019;54(1):10-16.
 18. Tarjan G. Schwannoma including epithelial elements mimicking pleomorphic adenoma of the submandibular gland on fine-needle cytology: The first case report. Diagn Cytopathol 2015;43(5):395-8.
 19. Wang H, Fundakowski C, Khurana JS, Jhala N. Fine-Needle Aspiration Biopsy of Salivary Gland Lesions. Arch Pathol Lab Med 2015;139(12):1491-7.
 20. Cantley RL. Fine-Needle Aspiration Cytology of Cellular Basaloid Neoplasms of the Salivary Gland. Arch Pathol Lab Med 2019;143(11):1338-1345.
 21. Li L-j, Li Y, Wen Y-m, Liu H, Zhao H-W. Clinical analysis of salivary gland tumor cases in West China in past 50 years. Oral oncology 2008;44(2):187-92.
 22. de Oliveira FA, Duarte ECB, Taveira CT, Máximo AA, de Aquino EC, de Cássia Alencar R *et al.* Salivary gland tumor: A review of 599 cases in a Brazilian population. Head and neck pathology 2009;3(4):271.
 23. Yorita K, Nakagawa H, Miyazaki K, Fukuda J, Ito S, Kosai M. Infarcted Warthin tumor with mucoepidermoid carcinoma-like metaplasia: A case report and review of the literature. J Med Case Rep 2019;13(1):12.
 24. Saha D, Tapadia R, Lobo FD, Dhavalpure N, Swamy M, Murali N. Lymphoepithelial Sialadenitis Involving HIV-Infected and Sjogren Syndrome Patients: A Cytologic Study. Indian J Otolaryngol Head Neck Surg 2019;71(2):176-181.
 25. Rossi ED, Faquin WC, Baloch Z, Barkan GA, Foschini MP, Puztaszeri M *et al.* The Milan System for Reporting Salivary Gland Cytopathology: analysis and suggestions of initial survey. Cancer Cytopathology. 2017;125(10):66-757.
 26. Baloch ZW, Faquin WC, Layfield LJ. Is it time to develop a tiered classification scheme for salivary gland fine-needle aspiration specimens? Diagnostic Cytopathology 2017;4(45):285-6.
 27. Wu HH, Alruwaili F, Zeng B-R, Cramer HM, Lai C-R, Hang J-F. Application of the Milan system for reporting salivary gland cytopathology: a retrospective 12-year bi-institutional study. American journal of clinical pathology 2019;151(6):613-21.
 28. Wang H, Malik A, Maleki Z, Rossi ED, Ping B, Chandra A, *et al.* "Atypical" salivary gland fine needle aspiration: risk of malignancy and interinstitutional variability. Diagnostic Cytopathology 2017;45(12):1088-94.
 29. Hollyfield JM, O'Connor SM, Maygarden SJ, Greene KG, Scanga LR, Tang S *et al.* Northern Italy in the American south: assessing interobserver reliability within the Milan system for reporting salivary gland cytopathology. Cancer cytopathology 2018;126(6):390-6.
 30. Song SJ, Shafique K, Wong LQ, LiVolsi VA, Montone KT, Baloch Z. The utility of the Milan System as a risk stratification tool for salivary gland fine needle aspiration cytology specimens. Cytopathology 2019;30(1):91-8.
 31. Bhutani N, Sen R, Gupta M, Kataria S. Moving toward A systematic approach for reporting salivary gland cytopathology: cytohistological correlation with the application of the Milan system for risk stratification at A tertiary care center. Diagn Cytopathol 2019;47(11):1125-1131.
 32. Ihrler S, Adam P, Guntinas-Lichius O, Harrison JD, Weiler C. Mustererkennung zur Differenzialdiagnose lymphoepithelialer Läsionen der Speicheldrüsen [Pattern recognition in the differential diagnosis of salivary lymphoepithelial lesions]. Pathologie 2009;30(6):432-41. German.
 33. Gadodia A, Seith A, Sharma R. Unusual presentation of Sjögren syndrome: Multiple parotid cysts. ENT: Ear, Nose & Throat Journal 2012;91(11).
 34. Wu L, Cheng J, Maruyama S, Yamazaki M, Tsuneki M, Lu Y *et al.* Lymphoepithelial cyst of the parotid gland: its possible histopathogenesis based on clinicopathologic analysis of 64 cases. Human pathology 2009;40(5):683-92.
 35. Muthureddy Y, Kathirvel C, Adakalam S. Role of fine needle aspiration cytology in salivary gland pathology and its histopathological correlation: A five year descriptive study in a tertiary care centre. Online Journal

- of Otolaryngology. 2015;5(4).
36. Uggas L, Ravanelli M, Pallottino AA, Farina D, Maroldi R. Diagnostic work-up in obstructive and inflammatory salivary gland disorders. Work-up diagnostico nella patologia ostruttiva e infiammatoria delle ghiandole salivari. *Acta Otorhinolaryngol Ital* 2017;37(2):83-93.