



ISSN (P): 2617-7226
ISSN (E): 2617-7234
www.patholjournal.com
2020; 3(3): 284-286
Received: 15-05-2020
Accepted: 19-06-2020

Dr. Damodaran AM
Associate Professor,
Department of Pathology,
Kanachur Institute of Medical
Sciences, Mangalore,
Karnataka, India

Dr. Shreesha Khandige
Professor and Head,
Department of Pathology,
Kanachur Institute of Medical
Sciences, Mangalore,
Karnataka, India

Fine needle aspiration cytology of Lymphadenopathies

Dr. Damodaran AM and Dr. Shreesha Khandige

DOI: <https://doi.org/10.33545/pathol.2020.v3.i3e.295>

Abstract

A study of FNAC of Lymphadenopathies” was taken up with objectives of studying the cytological features in lymphadenopathy and categorize them with respect to aetiology, age, sex and site of occurrence. Histopathological correlation of FNAC findings was done, wherever possible.

Keywords: FNAC, Lymphadenopathies, cross sectional

Introduction

Lymphadenopathy is one of the common clinical presentations of patients. It has a varied aetiology which varies from an inflammatory process to a malignant condition [1-8]. Fine Needle Aspiration Cytology (FNAC) is an accurate, simple and an easy diagnostic technique in evaluation of the causes of lymphadenopathy, and the reports can be made available within an hour that will form the basis of treatment, reduce the number of surgical procedures and unnecessary surgical intervention [9-14]. A study of FNAC of Lymphadenopathies” was taken up with objectives of studying the cytological features in lymphadenopathy and categorize them with respect to aetiology, age, sex and site of occurrence. Histopathological correlation of FNAC findings was done, wherever possible.

Aims and objectives

To study the role of FNAC in Lymphadenopathies.

Materials and methods

Thirty cases were studied in the Department of Pathology, Kanachur Institute of Medical Sciences, FNAC was done for the diagnosis of soft tissue tumors and reported.

Inclusion criteria

Only soft tissue tumors

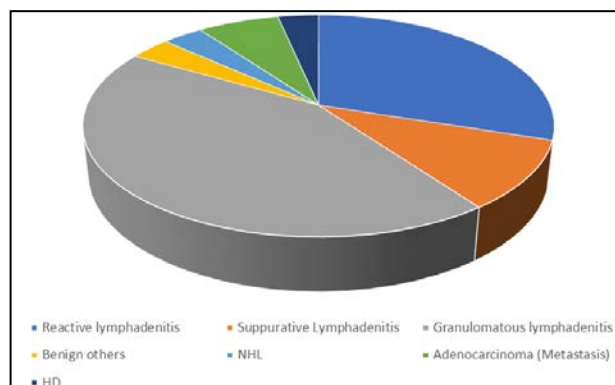
Exclusion Criteria

Patients on chemo or radio therapy.

Inflammatory diseases were not included.

Infections were not included.

Results



Graph 1: FNAC Diagnosis

Corresponding Author:
Dr. Shreesha Khandige
Professor and Head,
Department of pathology,
Kanachur Institute of Medical
Sciences, Mangalore,
Karnataka, India

Table 1: Sex Distribution

Male	14
Female	16

Table 2: Age distribution

Mean age	Std deviation
43.87 years	16.28 years

Table 3: FNAC Diagnosis

Reactive lymphadenitis	09
Suppurative Lymphadenitis	3
Granulomatous lymphadenitis	13
Benign others	01
NHL	01
Adenocarcinoma (Metastasis)	02
HD	01

Discussion

FNAC as a first line screening method has been recommended in suspected malignancy. The presence of granulomata in an aspirate may indicate the presence of a neoplastic process. The background cell population needs to be scrutinised if a malignant lymphoma is suspected. Granulomata may be encountered in both Hodgkin's disease and non-Hodgkin's lymphoma, particularly T-cell lymphoma [4]. Hodgkin's lymphoma is characterised by the classic Reed-Sternberg cells in a background of sarcoid-like granulomata, reactive lymphoid cells and occasional eosinophils [5-7]. Occasionally, lymph nodes containing metastatic carcinoma may also show features of granulomata. Previous reports have been described in metastatic nasopharyngeal carcinoma, seminoma and malignant melanoma [8, 9]. Histologically, non-caseating granulomata composed of epithelioid histiocytes with multinucleated giant cells are seen, but these can be indistinguishable from granulomatous inflammation from other causes. A series by Khurana *et al* [10]. Highlighted the difficulties encountered in making a definitive diagnosis of malignant neoplasm that mimics, or occurs, in association with granulomata.

Granulomatous inflammation found in lymph nodes draining carcinomas is a recognised phenomenon [10-12]. Such phenomenon are reported in pulmonary small cell carcinoma, [13] malignant melanoma, [9] papillary thyroid carcinoma, [14] gastric carcinoma, [15] and Rhabdomyosarcoma. This has been suggested to be either a response to necrotic material [12] or an immunological T-cell mediated hypersensitivity reaction to cell surface antigens. However, the precise mechanism is largely speculative as the exact tumour or host factors that enable such a response remain unknown.

A suspicious clinical history of TB (pyrexia, night sweats, recent travel to endemic areas, No previous BCG vaccination) coupled with positive aspirate, blood, sputum or urine tests for AFB and good response to anti-Tuberculous therapy supports the diagnosis of TB. One disadvantage is the inherent delay in culture result, but it is anticipated that as polymerase chain reaction and other amplification techniques become more common, detection time for the organism will shorten, improving the value of FNA in clinical practice. The typical FNAC features of toxoplasmosis include the presence of follicular hyperplasia

with secondary germinal centres rich in macrophages, presence of groups of epithelioid cells and presence of monocytoid histiocytes have been previously described. A combination of FNA features with positive serological testing and history of animal contact, as in the two patients here, gives the diagnosis of toxoplasmosis and thus avoids unnecessary surgical excision.

Sarcoidosis is a disease of unknown aetiology that can be characterised by the histological hallmark of epithelioid non-caseating granulomas, usually accompanied by multinucleated giant cells. The World Association and Other Granulomatous Diseases (WASOG) diagnostic criteria for sarcoidosis include that granulomata present in two or more organs with no agent known to cause a granulomatous response identified. Although there is no single gold standard test, the important role of FNAC in histological diagnosis and its underutilisation was highlighted by Tambouret *et al*. We agree with the authors that FNAC used in conjunction with clinical findings, radiological and laboratory investigations can be a cost effective method.

Conclusion

Lymphadenopathy is one of the commonest clinical presentations of patients, attending the outpatient Department and inpatient departments. Etiology varies from an inflammatory process to a malignant condition. FNAC diagnosis will help the clinician to confirm or exclude the clinical differential diagnosis made at first visit of the patient to the OPD. Speedy cytological diagnosis helps the clinician to further plan the treatment. Fine Needle Aspiration Cytology (FNAC) is an accurate diagnostic technique in diagnosing Etiology of lymphadenopathies. It is simple, easy technique and reports can be made available within an hour.

References

1. Ibrahim M. Zardavvi, Barry J. Barker, David P. Simons. Hodgkin's disease masquerading as granulomatous lymphadenitis on fine needle aspiration cytology Acta Cytol. 2005;48(2):224-226.
2. Gupta AK. Reliability and limitations of fine needle aspiration cytology of lymphadenopathies. An analysis of 1,261 cases Acta cytological. 1990;35(6):777-783
3. Raghuvver CV, Pai MR, Manohar C. Role of line needle aspiration cytology in disorders of lymph nodes, J of Cytol. 1996;13:45-49.
4. Patra AK, Nanda BK, Mohanpatra BK, Panda AK. Diagnosis of lymphadenopathy by line needle aspiration cytology, Indian J Pathol Microbiol. 1983;26:273-278.
5. John J Buchino, Faye Jones. Fine needle aspiration in evaluation of children in lymphadenopathy, Arch Pediatr Adolesc Med. 1994;148:1327-1330.
6. Raghuvver CV. Role of Fine needle aspiration cytology in disorder of lymph node, Journal of cytology. 1996;13:45-49.
7. D Malakar, ILN Jagoo, Kiran swamp, OP Gupta, AP Jain, VW Poflee. A clinical evaluation of fine needle aspiration cytology in the diagnosis of lymphadenopathy, Ind J Tub. 1991;38:12-20.
8. WF NG, Lgnatius TM Kung. Clinical research Pathology of tuberculously inpha dc nitis. Fine needle aspiration approach, J Honk Kong Med Ass. 1990;42(1):18-21.

9. SS Ahmad, SI Akhtar, K Akhtar, S Naseem, T Mansoor, S Khalil. Incidence of tuberculosis from study of fine needle aspiration cytology in lymphadenopathy and acid fast staining, *Ind J Com Med.* 2005;30:63-66.
10. RK Narang, S Pradhan, RP Singh, S Chaturvedi. Place of fine, needle aspiration cytology in the diagnosis of lymphadenopathy, *Ind J Tub.* 1990;037:29-30.
11. Yueh-lung Liu, Ya-Ting Lee, CT Sun-Wang Hsieh, Sow-HsongKuo. Presumption of primary sites of neck lymph node metastases on fine needle aspiration cytology, *Acta Cytol.* 1997;41:1447-1484.
12. Ruth L. Katz. Cytologic diagnosis of leukaemia and lymphoma, values and limitations, *Clinics in Lab Med.* 1991;11(2):469-98.
13. Uma Nahar Saikia, Pranab Dey, Babita Jindal, Biman Sakia. Fine needle aspiration cytology in Lymphadenopathy of HIV positive cases, *Acta Cytol.* 2001;45:589-592.
14. Kent Bottles, Laron W, Mcphau-I, Paul Volberding. Fine needle aspiration biopsy of patients with the acquired immunodeficiency syndrome (AIDS): Experience in an outpatient clinic, *Annals of Internal Medicine.* 1998;10S:42-45.