



ISSN (P): 2617-7226
ISSN (E): 2617-7234
www.patholjournal.com
2020; 3(3): 230-233
Received: 11-05-2019
Accepted: 12-06-2019

Dr. Anurag Mohan
Assistant Professor,
Department of Pathology,
Mata Gujari Memorial Medical
College and Lions Seva Kendra
Hospital, Kishanganj, Bihar,
India

Dr. Debi Prosad Dasgupta
Associate Professor,
Department of Pathology,
Mata Gujari Memorial Medical
College and Lions Seva Kendra
Hospital, Kishanganj, Bihar,
India

Dr. Ajay Kumar
Associate Professor,
Department of Pathology,
Mata Gujari Memorial Medical
College and Lions Seva Kendra
Hospital, Kishanganj, Bihar,
India

Corresponding Author:
Dr. Debi Prosad Dasgupta
Associate Professor,
Department of Pathology,
Mata Gujari Memorial Medical
College and Lions Seva Kendra
Hospital, Kishanganj, Bihar,
India

Histopathological study of salivary gland tumours in a tertiary care hospital

Dr. Anurag Mohan, Dr. Debi Prosad Dasgupta and Dr. Ajay Kumar

DOI: <https://doi.org/10.33545/pathol.2020.v3.i3d.287>

Abstract

Background: Salivary gland tumours constitute 3-10% of head and neck neoplasms. Their varied morphology poses challenge to pathologists as well as clinicians.

Methods: The present observational study included 99 cases of salivary gland tumours. Clinical details and findings of histopathological examination were noted.

Results: Mean age of the study subjects was 34.7 years. Female preponderance was seen. Most common site involved was parotid (64.7%). Most common tumour encountered was pleomorphic adenoma (76.5%). Malignant changes were seen in 17.6% cases. Most common malignant change seen was mucoepidermoid carcinoma (8.8%).

Conclusion: Malignant changes were seen in 17.6% cases. Pleomorphic adenoma was the most common benign neoplasm and mucoepidermoid carcinoma was the most common malignant tumour seen.

Keywords: Clinical features, observational study, pathology, salivary gland tumours

Introduction

Salivary gland swellings can be inflammatory, non-inflammatory and neoplastic in nature. Neoplastic swellings can be salivary calculi, benign tumours like pleomorphic adenoma, Warthin's tumour etc. while malignant tumours include adenocarcinoma, adenoid cystic carcinoma and others. These swellings may also be caused by connective tissue diseases such as haemangioma or neurofibroma, and auto-immune diseases like Sjogren's syndrome^[1].

These tumours are rare and constitute only 3% to 10% of the neoplasm of the head and neck region^[2]. The incidence of salivary gland tumours is 2.5-3 cases per 100,000 persons annually worldwide^[3]. Parotid gland is the site of lesion in about 80% cases while it is seen in submandibular gland in 10-15%. Salivary glands tumours can occur in any age and is seen more commonly in adults. Slight female predominance is seen. Benign tumours are more frequently seen than malignant tumours. Benign tumours are seen in approximately 80% of the parotid gland tumours while it is seen in 60% of the submandibular gland lesions. In the case of minor salivary gland lesions, malignant tumours are more commonly seen than benign tumours^[4].

Management of these tumours depends upon the histopathological findings. Knowledge about pattern of histopathological findings is helpful in planning for intervention and the facilities required. No such study has been conducted in this area recently. Hence, the present study was conducted.

Aims & objectives: The present study was conducted to identify the location and histological pattern of salivary gland tumours in patients presenting at a tertiary care hospital.

Material and methods

- **Study design:** The present study was hospital- based cross sectional in nature.
- **Study place:** The present study was conducted at the department of Pathology, Mata Gujari Memorial Medical College and Lions Seva Kendra Hospital, Kishanganj. It caters to patients from nearby districts of Bihar and West Bengal.
- **Period of study:** The present study was conducted between November 2018 to November 2019.
- **Study population:** The study population included adult patients found to be suffering

from salivary gland tumours and referred to the department of Pathology of the institute.

- **Inclusion criteria:** The patients above 18 years of age found to be suffering from salivary gland tumours who reported to the institute and were referred for histopathological examination were included in the present study.
- **Exclusion criteria:** Autoimmune, inflammatory, granulomatous swelling involving Major salivary glands and neoplasm involving minor salivary glands
- **Sampling technique:** All the samples of salivary gland tumours received in the department of Pathology during the study period were included. A total of 34 patients were studied.
- **Study tools:** Pre-tested proforma was used for data collection. It included questions related to demographic profile of the study subjects, their clinical history and the findings of histopathological examination.
- **Data collection procedure:** The study subjects were recruited from the pathology department of the institute whose salivary tumour specimens were sent to the department for histopathological examination. Details of the patients including demographic details, history of illness, location and size of tumours and other information like consumption of tobacco etc. were obtained. Findings of laboratory and radiological examinations were also noted. The excised tissue obtained in the department of Pathology were examined macroscopically. Before fixing, specimens were cut serially at a distance of 1 cm. It was fixed in 10% neutral buffered formalin for 24 - 48 hours. After fixation, the tumor proper and the margin of the tumor with surrounding tissue were selected for paraffin embedding. Four to five paraffin blocks of each specimen were prepared and sections of 3-5 microns thickness were cut. Microscopic sections were taken and staining was done with Haematoxylin & Eosin. Staining with PAS and Mucicarmin were done when required. The tumors were classified employing the new WHO international classification as a guideline.
- **Data analysis:** Data entry was done in Microsoft Excel 2010. Data analysis was done using Statistical Package for Social Sciences (SPSS) v 22.0. Quantitative data were summarized as mean and SD while qualitative data was expressed in terms of frequency and percentage. Appropriate statistical tests were done when needed. p-value <0.05 was considered to be statistically significant.
- **Ethical consideration & permission:** Permission was obtained from Institutional Ethics Committee. Informed consent was taken from all the study subjects. Those who did not give consent were not included. Confidentiality of records was maintained.

Results

Mean age of the study subjects was 34.7 years. Female preponderance was seen who constituted 61.8% of the

sample. Table- 1 shows the location of salivary gland tumours. Most common site involved was parotid (64.7%) followed by submandibular gland (14.7%). Minor salivary glands were involved in 20.5% cases.

Table 1: showing location of salivary gland tumours

Location	Frequency	Percentage
Parotid	22	64.7
Submandibular	5	14.7
Palatal	5	14.7
Buccal	1	2.9
Lip	1	2.9
Tongue	0	0
Total	34	100

Table-2 shows the histopathological findings. Most common tumour encountered was pleomorphic adenoma (76.5%). Warthin tumour was seen in 2.9% cases. Malignant changes were seen in 17.6% cases. Most common malignant change seen was mucoepidermoid carcinoma (8.8%). Gender-wise analysis showed that pleomorphic adenoma, monomorphic adenoma and mucoepidermoid carcinoma were more frequently seen in females.

Table 2: showing histopathological findings according to gender

Histopathological finding	Male	Female	Total	%
Pleomorphic adenoma	9	17	26	76.5
Monomorphic adenoma	0	1	1	2.9
Warthin tumour	1	0	1	2.9
Haemangioma	0	0	0	0
Mucoepidermoid carcinoma	1	2	3	8.8
Adenoid cystic carcinoma	1	1	2	5.9
Acinic cell carcinoma	1	0	1	2.9
Malignant mixed tumour	0	0	0	0
Total	13	21	34	100

Discussion

Salivary glands tumours are diverse in histology and presents varied morphological spectrum which can be seen between different histological types as well as within a particular tumour type. Tumours may present in hybrid pattern, may show dedifferentiation and some benign salivary gland tumours may show malignant changes [6]. These tumours are classified according to morphology. The histologic similarity with the underlying tissue may be misleading as its appearance may be different from the tissue of origin. World Health Organization has described nearly 40 different epithelial subtypes in the histological classification of salivary gland tumours [6]. In the present study aimed at evaluation of histopathological pattern of salivary gland tumours, 34 samples were examined. Mean age of the study subjects was 34.7 years. Female preponderance was seen who constituted 61.8% of the sample. Most common site involved was parotid (64.7%) followed by submandibular gland (14.7%). Minor salivary glands were involved in 20.5% cases. Most common tumour encountered was pleomorphic adenoma (76.5%). Warthin tumour was seen in 2.9% cases. Malignant changes were seen in 17.6% cases. Most common malignant change seen was mucoepidermoid carcinoma (8.8%) (Figure-1). Gender-wise analysis showed that pleomorphic adenoma, monomorphic adenoma and mucoepidermoid carcinoma were more frequently seen in females. Khedkar *et al.* in their study conducted in Pune found that the salivary

gland neoplasms had a mean age of 40.95 years. Mean age for benign neoplasms was 39.36 years and mean age for malignant neoplasms was 44.42 years. A male to female ratio of 1.06:1 was seen in this study. Major salivary glands were involved in 95% cases and parotid was the commonest site (88.47%). Minor salivary glands were involved in 5% of cases. Pleomorphic adenoma was the commonest benign neoplasm among benign neoplasms (87.5%). Mucoepidermoid carcinoma was seen in 70% of all malignant neoplasms [7].

Kumar *et al* in their study conducted in Kerala found that 57% tumours were benign and 43% were malignant. Most common age group for salivary gland tumour was between 40- 60 years. Female preponderance was seen in all tumours except Warthin tumour. Parotid gland was the most common site involved while adenoid cystic carcinoma showed predilection for the minor salivary glands. Pleomorphic adenoma was the most common benign tumour representing 76.3% of benign & 43.9% of total salivary gland neoplasms. Mucoepidermoid carcinoma was the common malignant tumour [8]. Theresa *et al*. in their study conducted in Puducherry found that 70.2% of tumours were benign while 29.8% were malignant. Pleomorphic adenoma was the most common benign neoplasm which is seen in 82.5% cases while Warthin's tumour was seen in 7.5% cases. Mucoepidermoid carcinoma was the most common malignant neoplasm (35.2%) followed by adenoid cystic carcinoma (29.4%) [9].

Saldanha *et al*. in their study conducted in Mangalore found an age range of 10-79 years. The most common site affected was the parotid gland (72.31%). 73.85% tumours were benign, pleomorphic adenoma (61.54 %) being the most common tumour. 26.15% cases were malignant and mucoepidermoid carcinoma (12.31%) was most frequently observed [10]. Sardar *et al*. in their study conducted in Mumbai found that the commonly seen tumours were pleomorphic adenoma (38.7%), basal cell adenoma (10.7%), mucoepidermoid carcinoma (21.3%) apart from adenoid cystic carcinoma, acinic cell carcinoma, adenocarcinoma and others [5]. Shinde *et al*. in their study conducted in Varanasi found that 61 % tumours were benign and 39 % were malignant. M:F proportion of 1.5:1 was seen. The mean age was 39.6 years. Pleomorphic adenoma was the commonest benign tumour, followed by Warthin tumour and basal cell adenoma. The mucoepidermoid carcinoma was the most common malignant tumour, followed by adenoid cystic carcinoma. The most common site involved

was parotid (68%) followed by submandibular (17%) and minor salivary organs (15 %) [11]. Srivani *et al*. in their study conducted in Telangana found that majority of benign tumours were seen in 4th decade while the malignant tumours were more common in the 6th decade. 81.2% tumours were seen in parotid gland, 11.3% in submandibular gland and 7.5% in the minor salivary glands. Benign tumours were seen in 75.47% cases and malignant tumours in 24.52%. The commonest benign tumour observed was pleomorphic adenoma (62.26%) followed by Schwannoma (5.64%), myoepithelioma (3.76%) and 1.88% each of Warthins tumour and monomorphic adenoma. The commonest malignant tumour was Adenoid cystic carcinoma (9.4%) followed by carcinoma- ex-pleomorphic adenoma (5.64%), polymorphous low-grade adenocarcinoma (5.64%) and mucoepidermoid carcinoma (3.76%) [12].

The findings of the present study are similar to observations of other researchers [4, 13-17]. Female preponderance was seen in the present study as also seen by Kumar *et al* but this finding varied between different studies.[8] Pleomorphic adenoma was found to be the most common benign tumour as observed in other studies. Mucoepidermoid carcinoma was the most common malignancy seen as also seen by Khedkar *et al*. [7] and Theresa *et al*. [9] but Srivani *et al*. [12] observed different pattern.

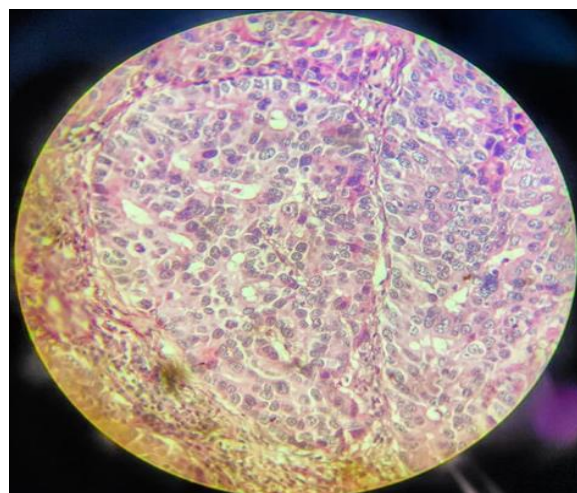


Fig 1: showing mucoepidermoid carcinoma of parotid gland

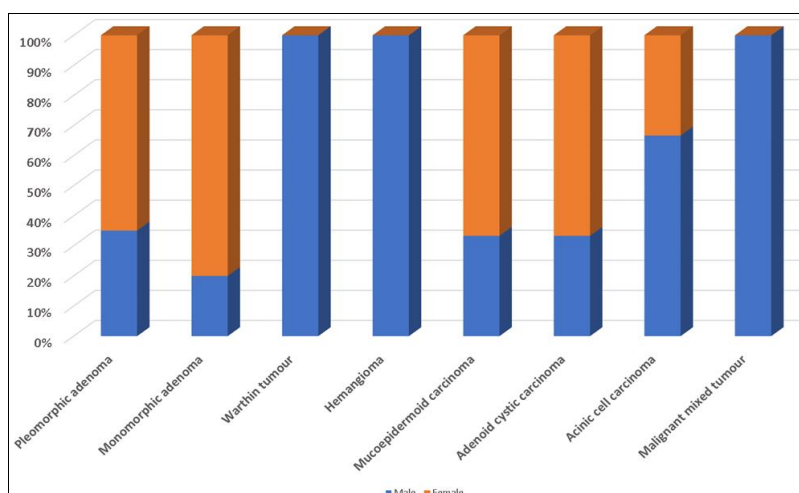


Chart 1: Showing gender wise histopathological findings

Conclusion

The present study described the histopathological pattern of salivary gland tumours in eastern part of Bihar. The findings of the present study were similar to the observations of other studies. The age-group, sex distribution and histopathological appearance matched with findings of other researchers. However, some of the studies reported different pattern depending upon the area and the patient profile. Most of the neoplasms were benign. Malignant changes were seen in 17.6% cases. Pleomorphic adenoma was the most common benign neoplasm and mucoepidermoid carcinoma was the most common malignant tumour seen.

References

1. Babu NS, Mahadev NH, V. KG. A clinical study of the incidence of salivary gland tumors in a tertiary care teaching hospital. *Int. Surg. J* 2019;6(6):2110-3.
2. Amin N, Shah S, Prajapati S, Goswami H. Histomorphological spectrum of salivary gland tumors in a tertiary care hospital; A retrospective study. *Int. J Med Sci. Public Health* 2017;6(2):299-302.
3. Dave P, Parikh U, Goswami H, Jobanputra G, Panchal N, Shah A. Histopathological study of salivary gland LESIONS. *Int. J Cur Res Rev* 2015;7(17):45-51.
4. Khattak M, Ahmad S, Noman N. THE histopathological pattern of salivary gland tumors. *Gomal Journal of Medical Sciences* 2016;14(4):203-7.
5. Sardar M, Ganvir S, Hazarey V. A demographic study of salivary gland tumors. *SRM J Res Dent Sci* 2018;9(2):6-73.
6. Badam R, Kanth S, Raju S, Kotha S, Rao M, Chandra KIP. Current concepts of salivary gland tumors. *J Orofac Sci* 2015;7(2):76-9.
7. Khedkar SS, Bhandari AP, Shirgaonkar NP. Clinicopathological Study of Salivary Gland Tumors. *APALM* 2020;7(5):A241-247.
8. Kumar DrAA, Hb DrR, Alva DrNK, Reginald DrSR. Histopathological spectrum of salivary gland neoplasms in a tertiary care center. *Int J Clin Diagn Pathol* 2019;2(1):243-6.
9. Margaret Theresa J, B Harke AML. A study on the morphological spectrum of salivary gland tumors. *IJPO* 2020;7(1):1-4.
10. Saldanha DC, Yaranal DP, Upadhyay K. A clinicopathological study of salivary gland tumors. *Pathology Update: Tropical Journal of Pathology & Microbiology* 2018;4(7):532-8.
11. Shinde P. Histopathological study of salivary gland lesions. *International Journal of Medical and Health Research* 2017;3(9):77-80.
12. Srivani N, Srujana S, Shhista S. Spectrum of salivary gland tumors - A five year study. *IAIM* 2016;3(7):132-6.
13. Gouthami S, Gattigorla S, Sheshagiri T. Cytomorphology and correlation with the histopathological diagnosis of salivary gland neoplasms. *IJIMS* 2018;5(9):752-8.
14. Ochicha O, Malami S, Mohammed A, Atanda A. A histopathologic study of salivary gland tumors in Kano, northern Nigeria. *Indian J Pathol Microbiol* 2009;52(4):473-6.
15. Rajdeo R, Shrivastava A, Bajaj J, Shrikhande A, Rajdeo R. Clinicopathological study of salivary gland tumors: An observation in tertiary hospital of central India. *Int J Res Med Sci* 2015;3(7):1691-6.
16. Reinheimer A, Vieira D, Cordeiro M, Rivero E. Retrospective study of 124 cases of salivary gland tumors and literature review. *J Clin Exp Dent* 2019;11(11):e1025-32.
17. Shishegar M, Ashraf MJ, Azarpira N, Khademi B, Hashemi B, Ashrafi A. Salivary Gland Tumors in Maxillofacial Region: A Retrospective Study of 130 Cases in a Southern Iranian Population. *Pathology Research International* 2011;2011:1-5.