



ISSN (P): 2617-7226
ISSN (E): 2617-7234
www.patholjournal.com
2019; 2(2): 93-95
Received: 13-05-2019
Accepted: 17-06-2019

Raja Chaterjee
Classified Specialist Pathology,
Military Hospital Secundrabad,
Telangana, India

Nitu Sharma
Classified Specialist Pathology,
Command Hospital Udhampur,
Jammu and Kashmir, India

Histopathological study of lesions in nasal cavity and nasopharynx in a tertiary care hospital

Raja Chaterjee, and Nitu Sharma

DOI: <https://doi.org/10.33545/pathol.2019.v2.i2b.85>

Abstract

Background: Lesions of nasal cavity are quite common. It can be neoplastic and non-neoplastic. Diseases of the nasal cavity include viral, bacterial and fungal infections, nasal cavity tumors as well as inflammations of the nasal mucosa. The main aim of this study was to study spectrum of histopathological lesions of nasal cavity, paranasal sinuses and nasopharynx in a tertiary care hospital.

Materials and Methods: This present descriptive, cross sectional study was conducted on 226 specimens of nose obtained from ENT department. After fixation, processing and H & E staining, histopathological diagnosis was made.

Results: Maximum specimens were obtained from age group 21-30 years (90), followed by 31-40 years (56), 11-20 years (48), 41-50 years (26) and >50 years (6). The difference was significant ($P < 0.05$). Non-neoplastic nasal lesions were 164 which comprised of polyps (132), mucormycosis (28), rhinophyma (4). Non neoplastic nasal lesions were 170 which comprised of polyps (136), mucormycosis (30), rhinophyma (4). Out of 38 neoplastic (benign) nasal lesions, inverted papilloma was seen in 22, hemangioma in 6, angiofibroma in 4, ossifying fibroma in 6. Out of neoplastic (borderline) nasal lesions, 2 were hemangiopericytoma. Out of 16 neoplastic (malignant) nasal lesions, SCC was seen in 8 and BCC in 8.

Conclusion: Lesions of nasal cavity and paranasal sinuses are of paramount importance because of high mortality and morbidity. Common nasal lesions were seen in age group 21-30 years and maximum lesions were non- neoplastic (benign) nasal lesions and neoplastic (benign) nasal lesions.

Key words: Nasal lesions, neoplastic, non-neoplastic

Introduction

Nose is the organ helps in smell as well as has aesthetic significance. It is most sensitive part of the face. The nasal cavity (or nasal fossa) is a large air filled space above and behind the nose in the middle of the face. Each cavity is the continuation of one of the two nostrils. Lesions of nasal cavity are quite common [1]. It can be neoplastic and non-neoplastic. Diseases of the nasal cavity include viral, bacterial and fungal infections, nasal cavity tumors as well as inflammations of the nasal mucosa. Deviated nasal septum, common cold, nasal polyp, nose bleed, rhinitis and broken nose are common lesions affecting nasal cavity. Nasal polyps are the most common cause of nasal obstruction. The most common causes are allergy, asthma and infections [2].

Polypoidal mass in the nose is a very common lesion encountered in clinical practice. It may be due to the most frequently occurring simple nasal polyp or polypoidal lesions due to a variety of other pathologic entity ranging from infective diseases to polypoid neoplasm including malignant ones. Tumors of nose are usually uncommon. Malignant tumors account for 0.2% to 0.8% of total malignancies and only 3% of all malignant tumors of upper aero digestive tract [3]. Masses in nasal cavity form a heterogeneous group of lesions with a broad spectrum of histopathological features [4]. A variety of these non-neoplastic and neoplastic lesions are quite impossible to differentiate clinically and they are clinically diagnosed as nasal polyp. The lack of differentiation between neoplastic and non-neoplastic, benign or malignant makes it neglected by the clinicians, as a result causing a delay in diagnosis and treatment.⁵ The main aim of this study was to study spectrum of histopathological lesions of nasal cavity, paranasal sinuses and nasopharynx in a tertiary care hospital.

Materials & Methods

This present descriptive, cross sectional study was conducted in the department of general pathology.

Correspondence
Nitu Sharma
Classified Specialist Pathology,
Command Hospital Udhampur,
Jammu and Kashmir, India

It comprised of 226 specimens of nose obtained from ENT department. Ethical clearance was taken from institutional ethical committee.

Information such as name, age, gender etc. was recorded in case history performa. All specimens were fixed in 10% formalin and kept overnight. After passing the tissue dehydration in graded alcohol for 6 hours each in three changes, clearing was done with two changes of xylene for hour each. Followed by this, impregnation and embedding in paraffin were done, blocks were prepared and 5µ sections were cut. The sections were stained with haematoxylin and eosin, dried and mounted in DPX and then microscopy was done. Data tabulated and analyzed to know relative frequencies of lesion presentation. P value less than 0.05 was considered significant.

Results

Table 1: Distribution of patients

Age group (Years)	Number	P value
11-20	48	0.02
21-30	90	
31-40	56	
41-50	26	
>50	6	

Table 1 shows that maximum specimens were obtained from age group age group 21-30 years (90), followed by 31-40 years (56), 11-20 years (48), 41-50 years (26) and >50 years (6). The difference was significant ($P < 0.05$).

Table 2: Histopathological diagnosis of lesions

Histopathological diagnosis	Numbers	P value
NON NEOPLASTIC NASAL LESIONS	170	0.01
Polyp	136	
Mucormycosis	30	
Rhinophyma	4	
NEOPLASTIC (BENIGN) NASAL LESIONS	38	
Inverted papilloma	22	
Hemangioma	6	
Angiofibroma	4	
Ossifying fibroma	6	
NEOPLASTIC (BORDERLINE) NASAL LESIONS	02	
Hemangiopericytoma	2	
NEOPLASTIC (MALIGNANT) NASAL LESIONS	16	
SCC	8	
BCC	8	

Table 2, figure 1 shows that Non neoplastic nasal lesions were 170 which comprised of polyps (136), mucormycosis (30), rhinophyma (4). Out of 38 neoplastic (benign) nasal lesions, inverted papilloma was seen in 22, hemangioma in 6, angiofibroma in 4, ossifying fibroma in 6. Out of neoplastic (borderline) nasal lesions, 2 were hemangiopericytoma. Out of 16 neoplastic (malignant) nasal lesions, SCC was seen in 8 and BCC in 8.

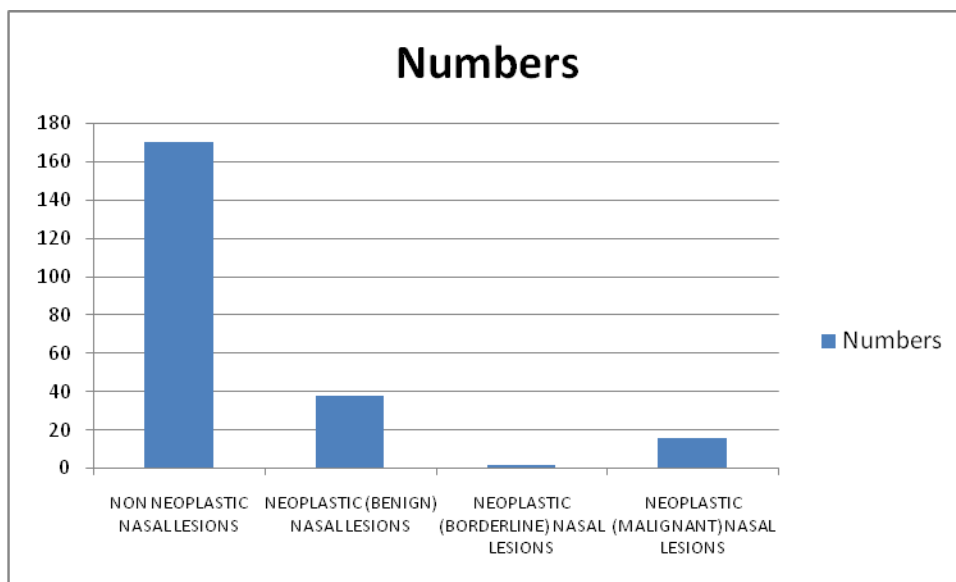


Fig 1: Shows lesions of nasal cavity and nasopharynx

Discussion

Heterogenous group of lesions with wide range of histomorphological variants are seen in the biopsies from masses of nasal cavity, paranasal air sinuses. It is quite difficult to differentiate clinically and they are routinely diagnosed as nasal polyp. A variety of non-neoplastic and neoplastic conditions involve the nasal cavity (NC), paranasal sinuses (PNS) and these are very common lesions encountered in clinical practice. A large number of diseases affecting these structures are due, to many of the specialized

tissues, each with its own aberrations that exist in the region [6]. The presenting features and symptomatology and advanced imaging technique help to reach a presumptive diagnosis but histopathological examination remains the mainstay of definitive diagnosis. Thus careful histological workup is essential for a correct diagnosis and timely intervention [7].

It is commonly seen in all age groups with no specific gender predilection. Common features are nasal blockage, nasal discharge, blocked nose, facial swelling etc. Nose is

the part which is constantly exposed to dust, chemicals, irritants and antigens. All this initiate disease of nasal cavity. Frequent recurrences and long duration of disease is problematic [8].

Benign lesions of nasal cavity (NC) and paranasal sinuses (PNS) are common. Malignant lesions in nasal cavity, paranasal sinuses and nasopharynx constitute approximately 1% of all the malignant tumours [9]. A wide range of variation in histopathological types and grades of malignancies has led the emergence of studying their clinical and pathological aspects. The exact nature of the lesion eliminates the confusion and strengthens the diagnosis. Thus by knowing the diagnosis, exact treatment can be given to the patient. It is beneficial for both clinician and patient [10]. The present study revealed that maximum specimens were obtained from age group 21-30 years (90), followed by 31-40 years (56), 11-20 years (48), 41-50 years (26) and >50 years (6). The difference was significant ($P < 0.05$). Similar study done by Chan SH *et al.* [9] also showed that males (68.29%) outnumbered the females (31.71%).

Bijjaragi *et al.* [11] found that out of 108 lesions, 52 were non-neoplastic and 56 were neoplastic lesion. 42 lesions were inflammatory polyp, 8 were fungal infection, 1 case each was of nasal glioma and rhinosporidiosis. 30 lesions were benign and 26 were malignant. The difference was significant ($P < 0.05$). Benign neoplastic lesions were inverted papilloma (14), schwannoma (6), angiofibroma (8) and capillary hemangioma (2). Malignant neoplastic lesions were squamous cell carcinoma (14), basal cell carcinoma (2), neuroblastoma (1), round cell tumor (3), PNT (1), plasmacytoma (4) and hemangiopericytoma (1).

We observed that Non neoplastic nasal lesions were 170 which comprised of polyps (136), mucormycosis (30), rhinophyma (4). Out of 38 neoplastic (benign) nasal lesions, inverted papilloma was seen in 22, hemangioma in 6, angiofibroma in 4, ossifying fibroma in 6. Out of neoplastic (borderline) nasal lesions, 2 were hemangiopericytoma. Out of 16 neoplastic (malignant) nasal lesions, SCC was seen in 8 and BCC in 8.

Parmar *et al.* [12] compared various histopathological lesions of nasal mass in relation to age, sex and site distribution. A histopathological study of total 100 cases of nasal lesions was done. Out of 100 cases, 59 were males and 41 were females. Male to female ratio was 1.44:1. Maximum numbers of nasal lesions were detected in age group of 11-20 years with 24 (24%) cases. Out of these 100 cases, 80 (80%) were non-neoplastic and 20 (20%) were of neoplastic origin. In neoplastic lesions, 12 (12%) were benign, 1 (1%) was borderline and 7 (7%) were malignant nasal lesions. Non neoplastic lesions were composed of the majority of cases followed by benign neoplastic lesions.

Modh SK. [13] in their study on 162 cases found that maximum neoplastic lesions were squamous cell carcinoma and plasmacytoma was the least in number. Similarly, in our study, most common was squamous cell carcinoma, basal cell carcinoma and haemangiopericytoma being a rare tumour. This is similar to observation by Parajuli *et al.* [8].

Conclusion

Lesions of nasal cavity and paranasal sinuses are of paramount importance because of high mortality and morbidity. Authors found that common nasal lesions were seen in age group 21-30 years and maximum lesions were

non- neoplastic (benign) nasal lesions and neoplastic (benign) nasal lesions. Histopathology is the key to differentiate one lesion from another which is beneficial for the management of lesion.

References

1. Zafar U, Khan N, Afroz N, Hasan SA. Clinicopathological study of non-neoplastic lesions of nasal cavity and paranasal sinuses. *Indian J Pathol Microbiol.* 2008; 51:26-29.
2. Randy Judd, Zaki SR, Lisa M, Coffield BS, Evatt BL. Sinonasal papillomas and Human papilloma virus. *Human Pathology.* 1991; 22:550-6.
3. Eggston AA, Wolf D. In: *Histopathology of Ear, Nose and Throat.* 2nd Edi. Williams and Wilkins, 1947.
4. Ackerman LY. *Surgical pathology, 6th Edi.* by Rosai. The Mosby Company St. Louis, 1996, 205.
5. Garg D, Mathur K. Clinico-pathological study of space occupying lesions of nasal cavity, paranasal sinuses and nasopharynx. *J Clin Diagn Res.* 2014; 8(11):42-8.
6. Mysorekar VV, Dandekar C, Rao S. Polypoidal lesions in the nasal cavity. *Bahrain Medical Bulletin.* 1997; 19(3):67-9.
7. Singh DT, Meshram K, Shreen S, Begum N, Vishwakarma S, Khan A *et al.* Role of histopathology in the diagnosis of nasal polypoidal masses. *Ind. J Applies Res.* 2015; 5(2):485-7.
8. Parajuli S, Tuladhar A. Histomorphological spectrum of masses of the nasal cavity, paranasal sinuses and nasopharynx. *J Pathol Nepal.* 2013; 3:351-5.
9. Chan SH, Day NE, Kunaratnam N, Chia KB, Simons MJ. HLA and nasopharyngeal carcinoma in Chinese. A further study. *Int. J Cancer* 1983; 32:171-176.
10. Sutar HB. Clinicopathological Study of Nasal Polypoidal masses. *Annual Inter Med Dental Res.* 2015; 1(3):315-9.
11. Bijjaragi S, Kulkarni VG, Singh J. Histomorphological study of polypoidal lesions of nose and paranasal sinuses. *Ind. J Basic App Med Res.* 2015; 4(3):435-9.
12. Parmar NJ, Jethwani DP, Dhruva GA. Histopathological study of nasal lesions: 2 years study. *Int. J Res Med Sci.* 2018; 6:1217-23.
13. Modh SK, Delwadia KN, Gonsai RN. Histopathological spectrum of sinonasal masses- A study of 162 cases. *Int. J Cur Res Rev.* 2013; 5(03):83-91.