



ISSN (P): 2617-7226
ISSN (E): 2617-7234
www.patholjournal.com
2018; 1(2): 28-29
Received: 14-11-2018
Accepted: 16-12-2018

Dr. Vishakha Sirpal
Medical Officer at Kamal
Hospital, Nakodar, District
Jalandhar, Punjab, India

Dr. Sidharth Sharma
Junior Resident, Department
of Internal Medicine, GMC,
Amritsar, Punjab, India

Dr. Harsh Kumar
Consultant Physician at Swami
Hari Giri Hospital Kakira
District Chamba Himachal
Pradesh, India

Dr. Prince Kumar
Consultant Physician at
Sukhmani Hospital, Zira,
Firozpur, Punjab, India

Pleomorphic fibroma of skin: A case report

**Dr. Vishakha Sirpal, Dr. Sidharth Sharma, Dr. Harsh Kumar and
Dr. Prince Kumar**

DOI: <https://doi.org/10.33545/pathol.2018.v1.i2a.08>

Abstract

Pleomorphic fibroma of skin (PFS) is a benign, polypoid, or dome-shaped cutaneous neoplasm with cytologically atypical fibrohistiocytic cells. We reported a case of PFS on the back of 55 years old male patient.

Keywords: Fibrohistiocytic, pleomorphic fibroma, polypoid

Introduction

Kamino *et al.* in 1989 described pleomorphic fibroma of the skin (PFS) which is a rare cutaneous fibrous tumor. PFS typically presents as a flesh-colored, dome-shaped papule on the trunk or extremities of middle-aged to older adults.¹ Rarely, PFS may appear at other sites such as the face and subungual area. The lesion is usually polypoid, located in the dermis, and is formed by coarse collagen bundles with sparse cells. It is also characterized by the presence of marked cellular atypia and pleomorphism without mitosis^[2].

Histologically, the lesion is sparsely cellular and composed predominantly of thick, haphazardly arranged collagen^[3]. Characteristic features are the presence of scattered, spindle-shaped, or stellate cells, including multinucleated giant cells with large pleomorphic, hyperchromatic nuclei and a small nucleolus. The lesion is almost always 0.5–2.0 cm in diameter and is often mistaken clinically for a nevus, neurofibroma, or hemangioma.⁴ We reported a case of PFS in 56-year-old male patient with fibroma on the back.

Case report

A 56-year-old male patient visited to the department of dermatology with complaint of asymptomatic subcutaneous lump on his back. History of presenting illness revealed that it gradually enlarged in the last 5 years to attain the present size.

Past medical history revealed that patient was otherwise healthy. On physical examination, the lesion was 2.5 cm in maximum diameter, slightly raised, mobile, elastic hard, and associated with slight erythema of the overlying skin. Based on the history and clinical features a provisional diagnosis of epidermal cyst was given. Patient was advised USG of the lesion. Ultrasonography showed an isoechoic to low echoic mass, 22.1 × 20.7 × 14.6 mm in size, with posterior acoustic enhancement and lateral shadowing.

Patient was subjected to laboratory investigations. The routine laboratory investigations were within normal limits. The lesion was surgically removed under local anesthesia and was sent to histopathological examination which showed a hypocellular lesion involving the reticular dermis and extending to the borders about the subcutis. The lesion was composed of haphazardly arranged, spindle-shaped cells with fusiform nuclei and eosinophilic cytoplasm, and stellate mononucleated cells with mild cytologic atypia in a collagenous stroma. There was neither acanthosis nor hyperpigmentation of the overlying epidermis. Neither mitotic figures nor necrosis were noted. Immunohistochemistry revealed that the lesional cells expressed vimentin, smooth muscle actin, factor XIIIa, CD99, and CD34 but was negative for S100 protein and desmin. Based on history, provisional diagnosis, histopathological findings, a final diagnosis of Pleomorphic adenoma of skin was given. Patient was recalled regularly over 1 year and we reported no recurrence of lesion.

Correspondence

Dr. Vishakha Sirpal
Medical Officer at Kamal
Hospital, Nakodar, District
Jalandhar, Punjab, India

Discussion

PF is a benign fibrous lesion which is located mainly in the lower extremities, followed by trunk, head, and neck and rarely in the subungual region. Most of these lesions occur in adults, with a peak incidence in the fifth decade of life^[5].

Some PFSs also have features of sclerotic fibromas. Indeed, some investigators postulate that PFS is actually a variant of sclerotic fibroma. Alternatively, other researchers have labeled these tumors as pleomorphic sclerotic fibromas. In present case, thickened and homogenized eosinophilic collagen bundles arranged in a laminated fashion with intervening prominent clefts were absent; hence it was diagnosed as PFS rather than sclerotic or pleomorphic sclerotic fibroma^[6].

PFS may clinically resemble a nevus, neurofibroma, hemangioma, fibrokeratoma, or fibroepithelial polyp. A provisional diagnosis of epidermal cyst as the lesion was mobile, elastic hard, and slightly raised, and ultrasonography revealed an isoechoic to low echoic mass with posterior acoustic enhancement and lateral shadowing.⁷ PFS can easily be misdiagnosed as malignant soft tissue tumor because it contains bizarre pleomorphic cells showing considerable atypia. This lesion has been shown to be benign despite the presence of pleomorphic or bizarre cells, although lesion may locally recur when incompletely excised. This also reveals the importance of mitosis and necrosis in making a diagnosis of malignant soft tissue tumor on cytology, as both these features were not seen in this tumor^[8].

Histopathological findings of PFS may lead to the inclusion of malignancy in the differential diagnosis. Careful histological examination will readily distinguish PFS from the more cellular tumors of malignant fibrous histiocytoma and atypical fibroxanthoma, which contain cells arranged in a fascicular to storiform pattern with foamy cytoplasm and frequent (sometimes atypical) mitotic figures. In our case, cytologic atypia was present, but neither mitotic figures nor necrosis were observed; thus, we believe that the cytologic pleomorphism may have been part of a degenerative process.

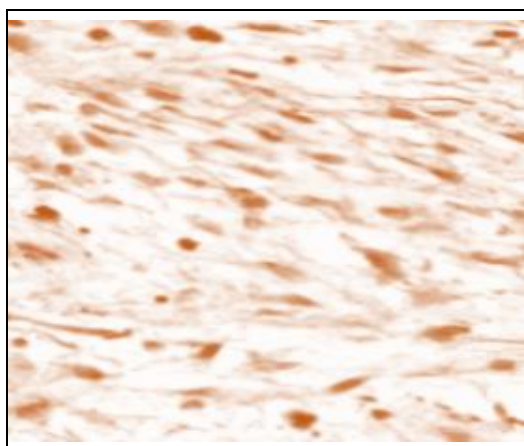


Fig 1: Histopathology of PF

Giant cell fibroblastoma is usually seen in childhood and is characterized by infiltrative growth and features sinusoidal structures lined by atypical cells, whereas our case was an adult without infiltrative growth and sinusoids.^[9] Desmoplastic Spitz nevus and desmoplastic melanoma show

some areas of melanocytic differentiation and cells are positive for S-100 protein, both these features were absent in present case.

Conclusion

Pleomorphic fibroma of the skin is not uncommon. Careful evaluation and management can be useful in preventing recurrence of the lesion.

References

1. Yadav YK, Kushwaha R, Sharma U, Gupta K. Cytomorphology of pleomorphic fibroma of skin: A diagnostic enigma. *J Cytol.* 2013; 30:71-3.
2. García-Doval I, Casas L, Toribio J. Pleomorphic fibroma of the skin, a form of sclerotic fibroma: an immunohistochemical study. *Clin Exp Dermatol.* 1998; 23:22-4.
3. Pitt MA, Roberts IS. Myxoid cutaneous pleomorphic fibroma. *Histopathology.* 1994; 25:300.
4. Miliauskas JR. Myxoid cutaneous pleomorphic fibroma. *Histopathology.* 1994; 24:179-81.
5. Martin-Lopez R, Feal-Cortizas C, Fraga J. Pleomorphic sclerotic fibroma. *Dermatology.* 1999; 198:69-72.
6. Mahmood MN, Salama ME, Chaffins M, Ormsby AH, Ma CK, Linden MD *et al.* Solitary sclerotic fibroma of skin: A possible link with pleomorphic fibroma with immunophenotypic expression for O13 (CD99) and CD34. *J Cutan Pathol.* 2003; 30:631-6.
7. Chen TM, Purohit SK, Wang AR. Pleomorphic sclerotic fibroma: A case report and literature review. *Am J Dermatopathol.* 2002; 24:54-8.
8. Rudolph P, Schubert C, Zelger BG, Zelger B, Parwaresch R. Differential expression of CD34 and Ki-M1p in pleomorphic fibroma and dermatofibroma with monster cells. *Am J Dermatopathol.* 1999; 21:414-9.
9. Kamino H, Lee JY, Berke A. Pleomorphic fibroma of the skin: A benign neoplasm with cytologic atypia. A clinicopathologic study of eight cases. *Am J Surg Pathol.* 1989; 13:107-13.