



ISSN (P): 2617-7226  
ISSN (E): 2617-7234  
www.patholjournal.com  
2018; 1(2): 18-20  
Received: 15-01-2019  
Accepted: 16-02-2019

**Dr. Indudhara PB**  
Associate Professor, Subbaiah  
Institute of Medical Sciences,  
Shivamogga, Karnataka, India

**Dr. Ganga H**  
Assistant Professor, Subbaiah  
Institute of Medical Sciences,  
Shivamogga, Karnataka, India

**Dr. Yenni**  
Professor Emeritus, Subbaiah  
Institute of Medical Sciences,  
Shivamogga, Karnataka, India

## Role of bone marrow aspiration and bone marrow biopsy in routine practice

**Dr. Indudhara PB, Dr. Ganga H and Dr. Yenni**

**DOI:** <https://doi.org/10.33545/pathol.2018.v1.i2a.05>

### Abstract

**Introduction:** Bone marrow examination is useful and cost effective, day care procedure. These studies are preceded by evaluation of medical history, clinical features, CBC and peripheral smear. Bone marrow aspiration and biopsy are complimentary to each other. Aim of the study is to correlate aspiration and biopsy findings in routine practice.

**Methods and materials:** This is a prospective study carried out between Jan 2018 to Dec 2018 in SUIMS, Shimoga. Total of 28 cases were diagnosed. Bone marrow aspiration slides were stained with leishman and bone marrow biopsy were routinely processed and stained with H&E, reticulin and perl stain whenever necessary.

**Results:** Males were commonly exposed to bone marrow study compared to females. Anemia under evaluation was common indication for bone marrow aspiration. Commonest bone marrow aspiration diagnosis was Megaloblastic marrow. There were two dry taps, where in biopsy was diagnostic.

**Discussion:** Bone marrow aspiration was sufficient in 92% of cases. The positive correlation between BMA and BMB was 89.2%. The diagnostic accuracy of BMA was 92% where as that of BMB was 100%. Trepine biopsy was very useful in MDS and MF.

**Conclusion:** BMA and BMB complement each other. Biopsy has been useful when ever aspiration has yielded low cellularity. It is advisable to follow aspiration with biopsy for better results.

**Keywords:** Bone marrow aspiration, bone marrow biopsy, trephine biopsy

### Introduction

The technique of bone marrow aspiration has been accepted and widely used [1]. Aspiration biopsies are carried out principally to permit cytological assessment of bone marrow cells. In many patients a trephine biopsy will be carried out as a part of same procedure [2]. Bone marrow examination is a useful and cost effective diagnostic procedure in haematological practice for the diagnosis of both neoplastic and non-neoplastic haematological diseases [3]. Bone marrow aspiration should be preceded by evaluation of medical history and clinical features, examination of blood film and assessment of results of full blood count, other lab tests and radiological investigations [2]. Now a days aspirate and trephine biopsy are considered complimentary and when both are obtained, they provide a comprehensive study of bone marrow [3]. Bone marrow study is of greater help in pancytopenia, myeloproliferative disorder, CLL, NHL and pyrexia of unknown origin<sup>2</sup>. The aim of the study is to correlate bone marrow aspiration and biopsy findings in various haematological diseases.

### Methods and Materials

This is prospective study conducted between JAN 2018 to DEC 2018 in SUIMS, Shimoga over a period of one year. A total of 28 cases were done with bone marrow aspiration and most them were followed with bone marrow biopsy except one. Every case is investigated with CBC, Peripheral smear and ultrasonography of abdomen when ever necessary. Indication for bonemarrow examination with informed consent of patients included red cell disorders, leucocytic disorders, platelet disorders, MPD, PUO, metastasis and unexplained hepatomegaly or splenomegaly. People with coagulation disorders, skin infection at posterior superior iliac spine were not considered for study.

Before doing bone marrow aspiration patient is tested with lignogaine on forearm and given inj tramadol to ease suction pain. For bone marrow aspiration salah needle (14 G) and for biopsy (11 G) is preferred. Needles and instruments were autoclaved.

### Correspondence

**Dr. Ganga H**  
Assistant Professor, Subbaiah  
Institute of Medical Sciences,  
Shivamogga, Karnataka, India

The usual site for BMA is right posterior superior iliac spine. After wearing disposable non powdered gloves, area was cleaned with spirit, betadine and again with spirit. 5 to 10 ml of lignocaine 2% is injected subcutaneously and in to the periosteum. An effort is made to gauge depth and thickness of periosteum while injecting lignocaine. After enough time for local anaesthetic to act, Salah needle with stillette is introduced with screwing motion in to the bone at RPSIS. Once the needle reaches bone marrow space, there will be 'giving in sensation'. Stillette is then taken back, keeping needle in place. 10 cc of syringe is attached to salah and 0.25 to 0.40ml of marrow material is aspirated. Patient usually complains of pain during suction. Needle is removed from PSIS and material put on to slides. While the operator prepares smear, an helping assistant puts pressure an BMA site with gauze piece to achieve haemostasis. Material on slides are spread by placing two slides on each other and pulling them apart in opposite direction. For bone marrow biopsy, Jamshidi needle is introduced at near by site, adjacent to BMA. A small nick is made with scalpel blade (number 11) on skin. Needle with

stillette is introduced till bone surface. Once it reaches bone, stillette is removed and with screwing motion needles is inserted in the direction of ASIS for another 1 to 1.5 cm. needle is loosened from surrounding and retrieved. Biopsy is expelled forward with help of stillette. Operator's assistant maintains firm pressure for another 5 mins and site is covered with bandage. Patient is asked to lie in supine position for next 20 to 30mins. For bone marrow aspiration, leishman staining is used. Biopsy was fixed in formalin overnight, and decalcified using EDTA 10% for one or two days and then taken for processing. Slides were stained with H&E routinely, reticulin and perls stain when ever necessary.

**Results**

In our study of one year period, we came across 28 cases on which we did BMA. BMA was followed with BMB except for one. Maximum cases were in the age group of 41 to 50 years and less in children. (Table 1). Male to female ratio was 3.6 to 1. Males were commonly (78%) exposed to BM studies compared to women. (Table 2).

**Table 1:** Age distribution among BMA cases.

Age	0-10	11-20	21-30	31-40	41-50	51-60	61-70	71-80
BMA	1	1	3	5	8	1	5	4

**Table 2:** Sex distribution among BMA cases

Male	22	78%
Female	6	22%
Total	28	

Among clinical indications for bone marrow aspiration, anemia under evaluation was commonest, followed by pancytopenia (Table 3). Commonest bone marrow aspiration diagnosis was Megaloblastic marrow followed by Acute leukemia. Least was normoblastic marrow (Table 4). Cases of leukemia and thrombocytopenia were consistent in marrow findings. One case of Anemia under evaluation on peripheral smear was later diagnosed to be multiple myeloma. Bone marrow aspiration had a significant outcome in two pancytopenia cases, one was megaloblastic marrow and other lympho proliferative lesion. Rest two pancytopenia cases gave rise to dry taps, where we failed to obtain bone marrow material on repeated aspiration. They were diligently followed up with bonemarrow biopsy. Trepine biopsy in most cases complimented diagnosis made on aspiration.

**Table 3:** Indications for BMA

Anemia	18	64%
Pancytopenia	04	14%
Leukemia	03	10%
Thrombocytopenia	02	7%
Multiple myeloma/? Backache	01	3%
Total	28	

Commonest diagnosis was Megaloblastic marrow followed by acute leukemia and less common finding was hypercellular marrow (Table 5). Of the two dry taps, one turned out to be Myelofibrois and other Myelodysplastic syndrome. Trepine biopsy also facilitated molecular studies.

**Table 4:** Common diagnosis on Bonemarrow aspiration.

Megaloblastic marrow	17	60%
Acute leukemia	03	10%
ITP	02	7%
Plasma cell dyscrasia/ Multiple myeloma	02	7%
Normoblastic hypercellular	01	3%
Lymphoproliferative	01	3%
Drytaps	02	7%
Total	28	

**Table 5:** Common diagnosis on bone marrow biopsies.

Megaloblastic marrow	17	62%
Acute leukemia	03	11%
ITP	02	7%
Multiple myeloma	02	7%
Myelofibrosis	01	3%
Myelodysplastic syndromes	01	3%
Hypercellular marrow	01	3%
Total	27	

**Discussion**

Sabharwal BD *et al.* stated that core needle biopsy of bone marrow is a valuable diagnostic aid foe measurement of cellularity, metastatic tumours and fibrosis [4]. Bone marrow biopsy is complimentary to aspiration for most cases in our study. Aspiration is useful in making out better individual cell morphology where as biopsy is useful in marrow architecture pattern and distribution [2]. There was 89.2% positive correlation between bonemarrow aspiration and bone marrow biopsy in our study. Bone marrow aspiration was sufficient to make diagnosis in 92% of cases, some what similar to Nanda *et al.* [5]. in remaining 7.2% cases biopsy was necessary for making diagnosis. These cases were clinically pancytopenia and on biopsy turned out to be MF (Figure 1) and MDS (Figure 2). The diagnostic accuracy of BMA is 92% in comparison to BMB which is 100%,

correlates well with Smitha Chandra *et al.* [6], who has given diagnostic accuracy for BMA of 77.5% and for bone marrow biopsy of 99.2%. commonest BMA diagnosis in our study was anemia (60.7%) similar to Biradar *et al.* [1]. One clinical case of anemia was diagnosed by BMA as multiple myeloma (Figure 3). In our present study 3 cases of leukemia were diagnosed on BMA. Trepine biopsy was used for providing additional information. All 3 leukemias were diagnosed to be of acute leukemia similar to Patil *et al.* [7]. Two cases of ITP were diagnosed on BMA (7%) similar to Patil *et al.* [7]. There were two cases of multiple myeloma on BMA (7%), one of which presented only with anemia. Bone marrow biopsies from these cases yielded small fragments of bony tissue. Myelofibrosis and Myelodysplastic syndrome were solely diagnosed by biopsy where as BMA yielded only dry tap.

### Conclusion

Bone marrow examination includes BMA and BMB which act complimentary to each other. They are useful, cost effective, day care procedures. Bone marrow aspiration is useful in cytological examination of bone marrow. Architectural details are better appreciated in trephine biopsy. Biopsy has been useful whenever aspiration has yielded low cellularity. With significant positive correlation, increasing accessibility and ease of doing, it is advisable to follow up aspiration with biopsy.

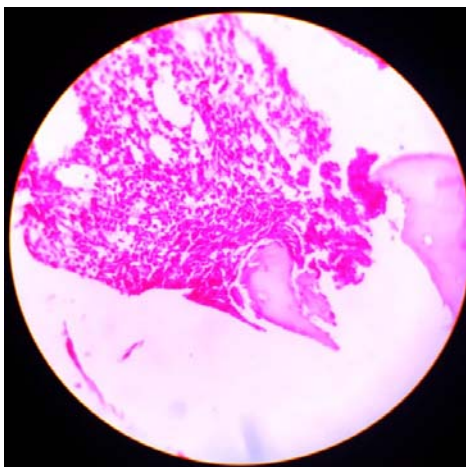


Fig 1: Myelofibrosis in low power view (10X) H&E Stain

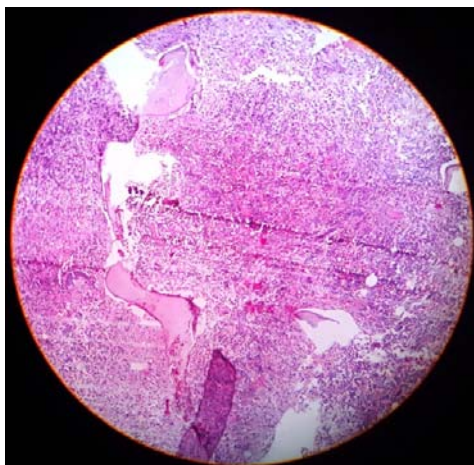


Fig 2: MDS in low power view (10X) H&E Stain

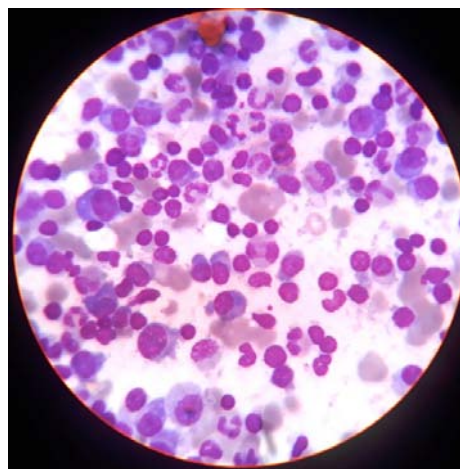


Fig 3: Multiple myeloma in low power view (10X) Leishman Stain.

### References

1. Dr. Praveen B, Biradar, Dr. Manjula Praveen Biradar. A Study of Bone marrow aspiration and biopsy in various haematological Disorders. International Journal of Scientific Research. 2017; 6(5):174-175.
2. Bain BJ. Bone marrow aspiration. J Clin Pathol. 2001; 54:657-663.
3. Dr. Shilpa Patel, Dr. Pooja Nathani, Dr. Nailesh Shah, Dr. Shah CK. Diagnostic Role of Bone Marrow Aspiration and Trepine Biopsy in Haematological Practice. Gujarat Medical Journal. 2015; 70(2):37-41.
4. Sabharwal BD, Malhotra V, Aruna S, Grewal R. Comparative evaluation of Bonemarrow Aspiration particle smear, imprints and biopsy sections. Journal of Post graduate Medicine. 1990; 36:194-208.
5. Nanda A, Basu S, Marwaha N. BMB as an adjunct to BMA. J Assoc Physicians India. 2002; 50:893-5.
6. Smita Chandra, Harish Chandra. Comparison of bone marrow BMA cytology, BMI cytology and BMB for bone marrow evaluation. Hematology Reports, 2011; 3:e22.
7. Lalita Y Patil, Yoganand V Patil, Grace D'Costa, Arvind Valand. Diagnostic utility of bone marrow aspiration and biopsy in paediatric age group. International Journal of Contemporary Medical Research. 2016; 3(8):2310-2313.